

# *Challenges Correlating Molecular and Histological Findings in Surgical Pathology*

Dr. Alexander Mackinnon, Jr,  
M.D., Ph.D., M.S.H.A

## Speaker Objectives:

- Examine potential pitfalls in molecular testing
  - Identify root causes to explain discordant results
- Explore the role of underlying genetic conditions in unexpected lab results





# Challenges Correlating Discordant Molecular and Histological Findings in Surgical Pathology

Alexander C. Mackinnon, MD, PhD, MSHA  
Executive Vice Chair & Robert B. Adams Endowed Professor  
University of Alabama at Birmingham

**11<sup>th</sup> Annual Medical & Clinical  
Laboratory Sciences Symposium**

**April 4, 2025**

**Auburn University at Montgomery**

# Conflict of Interest

**Nothing to disclose**

**Sincere thank you to the Robert B. Adams Family for  
generous support to UAB Pathology**

# Objectives

Use a case-based approach to present discordant tissue-based and molecular testing results

- Tumor heterogeneity and sampling
- Potential underlying germline mutations
- Discordant molecular-histological findings


Examine potential pitfalls, roots causes, and best practices for discordant lab results

**UAB** THE UNIVERSITY OF  
ALABAMA AT BIRMINGHAM.

DEPARTMENT OF PATHOLOGY

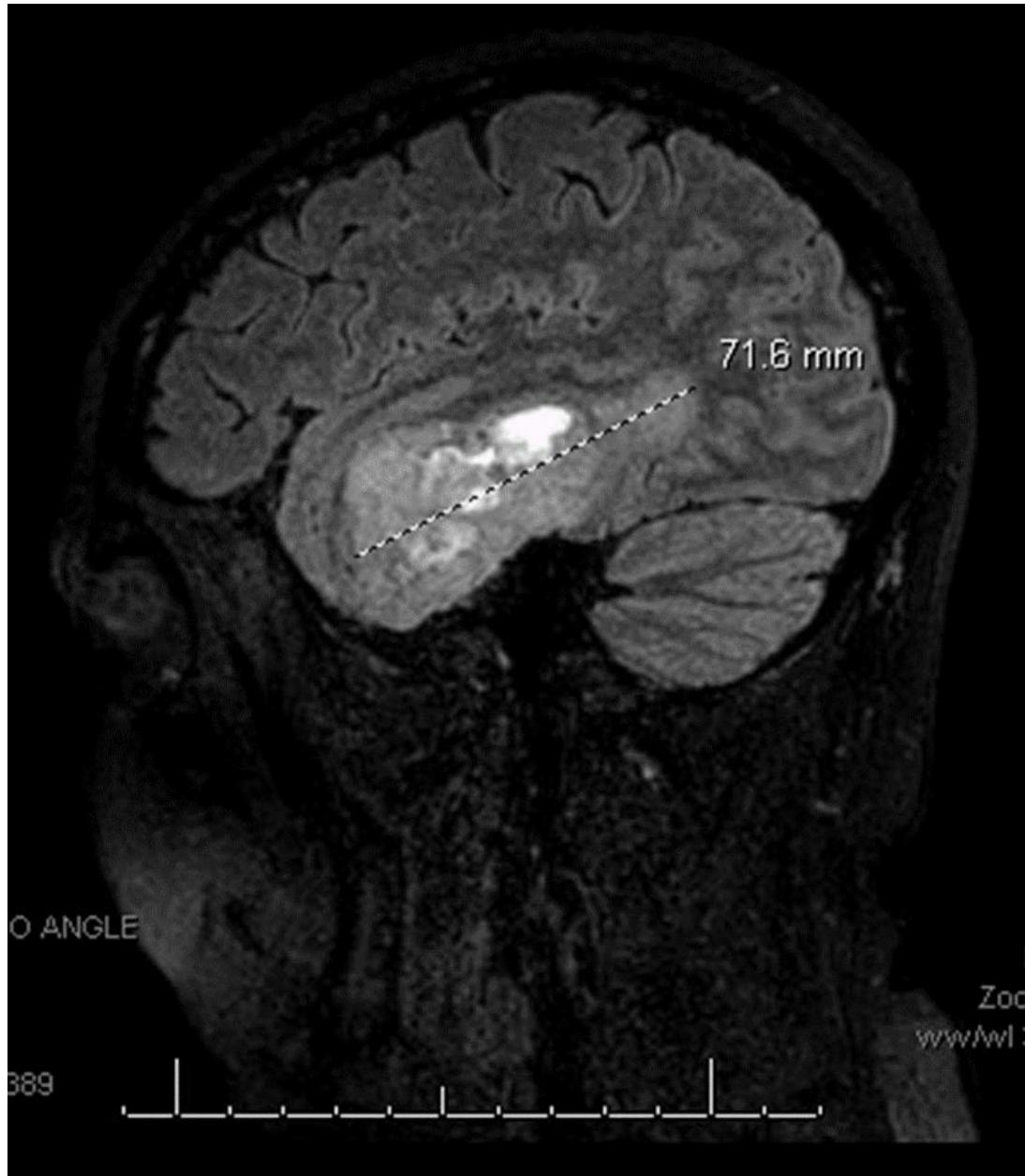
# Case 1

## *Tumor Heterogeneity*



**Bartow, Brooke, M.D.**  
**UAB PGY4**  
**AP/CP Resident**

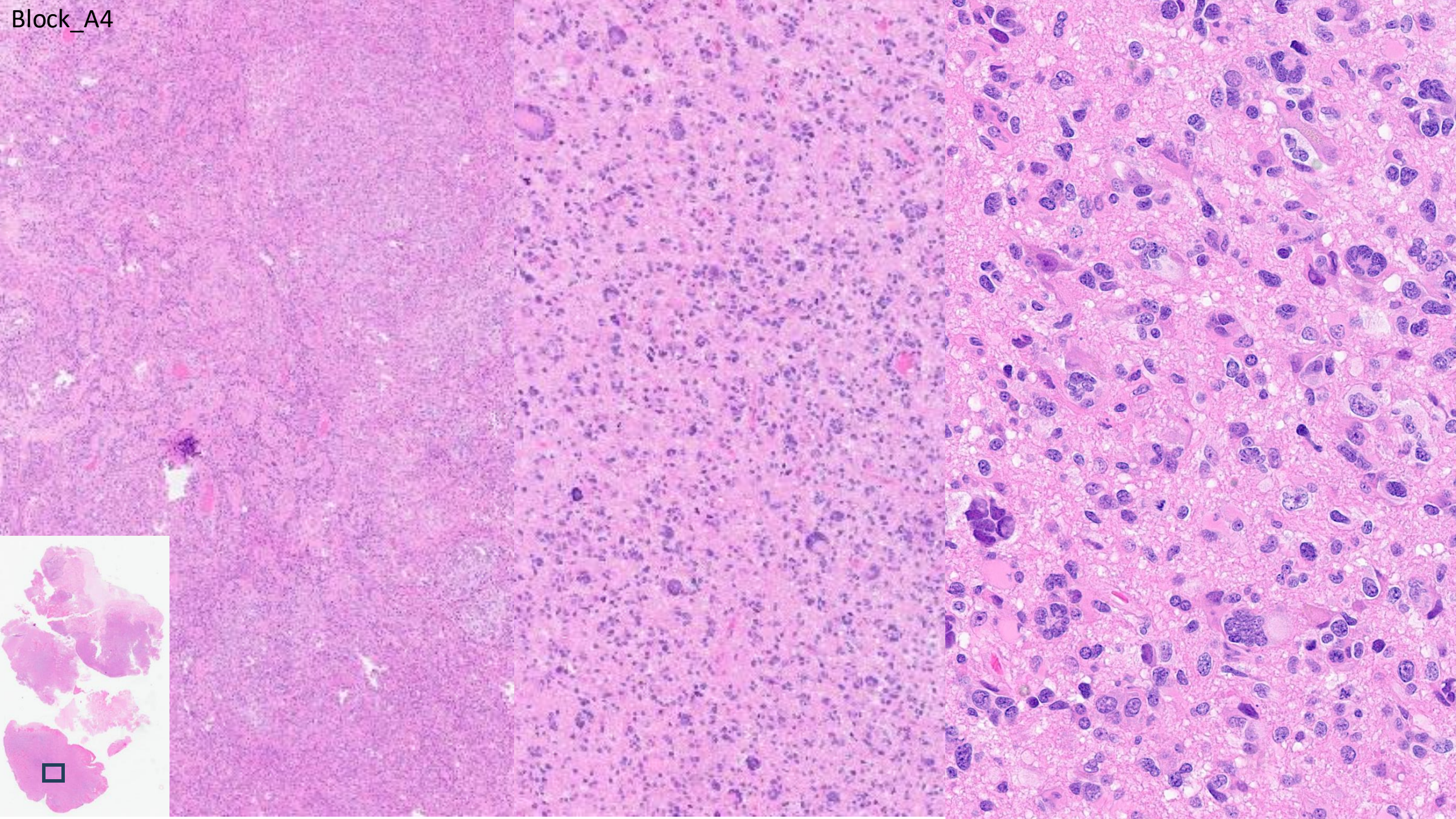
# MRI: expansile partially hemorrhagic lesion within the left temporal lobe.



The patient is a 56-year-old female presenting with new onset seizures. MRI demonstrated an expansive, partially hemorrhagic lesion within the left temporal lobe.

# Histology

- Highly cellular, infiltrating tumor composed of atypical/pleomorphic glial cells with hyperchromatic, angulated nuclei.
- Epithelioid, gemistocytic, and large multinucleated forms are identified.
- Mitotic activity is brisk.
- Tumor necrosis and microvascular proliferation are identified.



# IHC Results

GFAP: Positive in majority of tumor cells, including epithelioid areas

Olig2: Subset positive in tumor nuclei

IDH1 R132H: Negative

ATRX: Retention in tumor nuclei

p53: Elevated Staining in tumor cell nuclei

**BRAF V600E: Positive cytoplasmic staining in focal/subset of tumor cells**

Reticulin: Positive pericellular staining in a subset of tumor cells

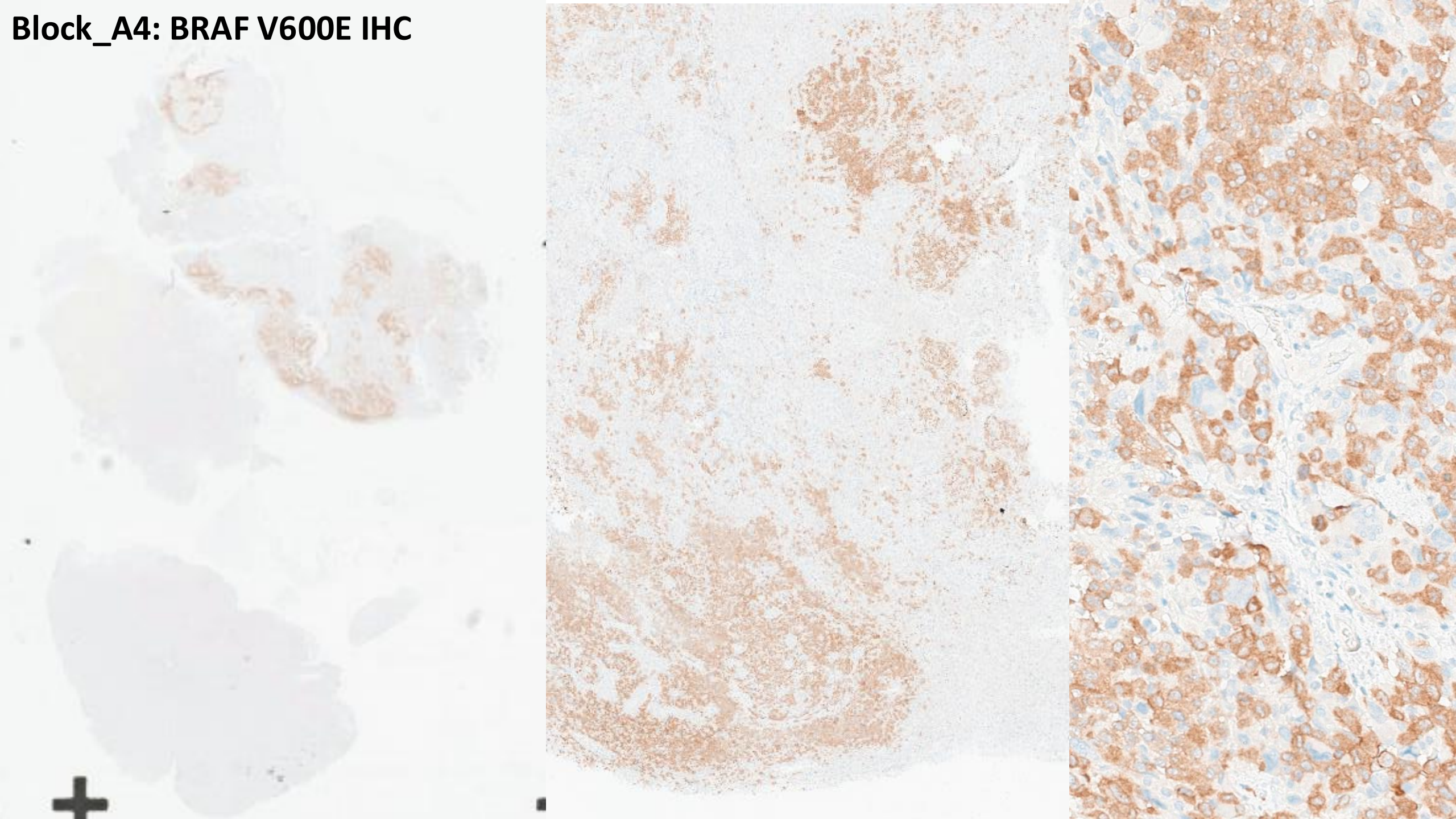
MLH1: Retained/wild-type staining pattern

MSH2: Retained/wild-type staining pattern

MSH6: Retained/wild-type staining pattern

PMS2: Retained/wild-type staining pattern

Block\_A4: BRAF V600E IHC

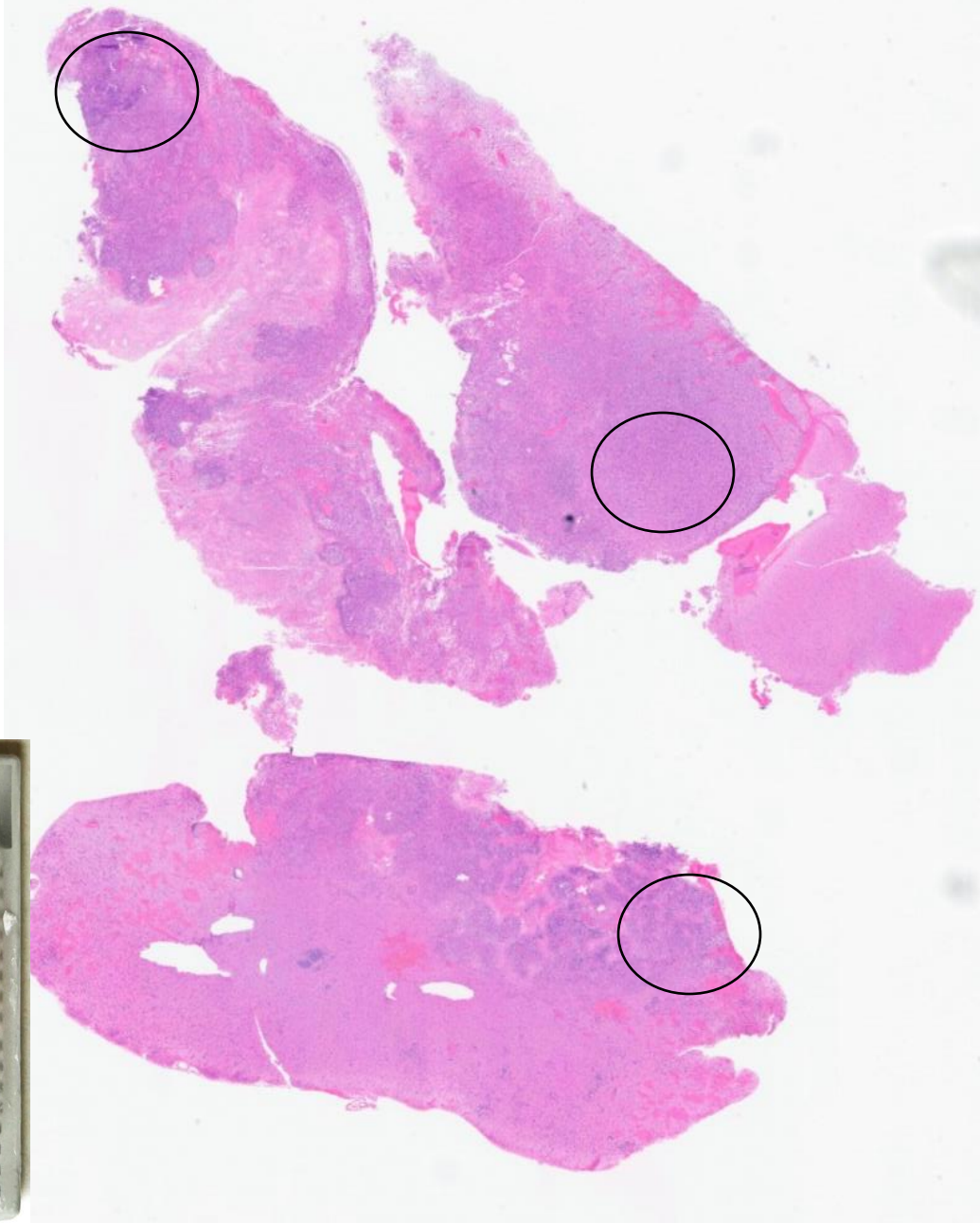


# Diagnosis

Brain, left temporal mass, resection:

- High-grade infiltrating glioma, NOS (see comment)
- IDH1 R132H negative by immunohistochemistry
- BRAF V600E positive by immunohistochemistry in a subset of cells
- IHC done on **block A4**
- Send **block A6** to Molecular Lab for NGS

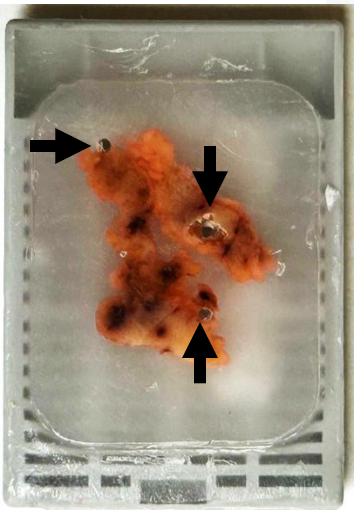
## Block\_A6: Used for NGS



1mm tissue cores obtained from tumor rich areas  
DNA/RNA extracted and tested for mutations  
50 gene Next Generation Sequencing (**NGS**) panel

<u>Gene</u>	<u>Variant</u>
GNA11	p.Q105H
STAG2	c.2534-1G>A
TERT	c.-124C>T
TMPRSS2	p.Q88R
TP53	p.P223L

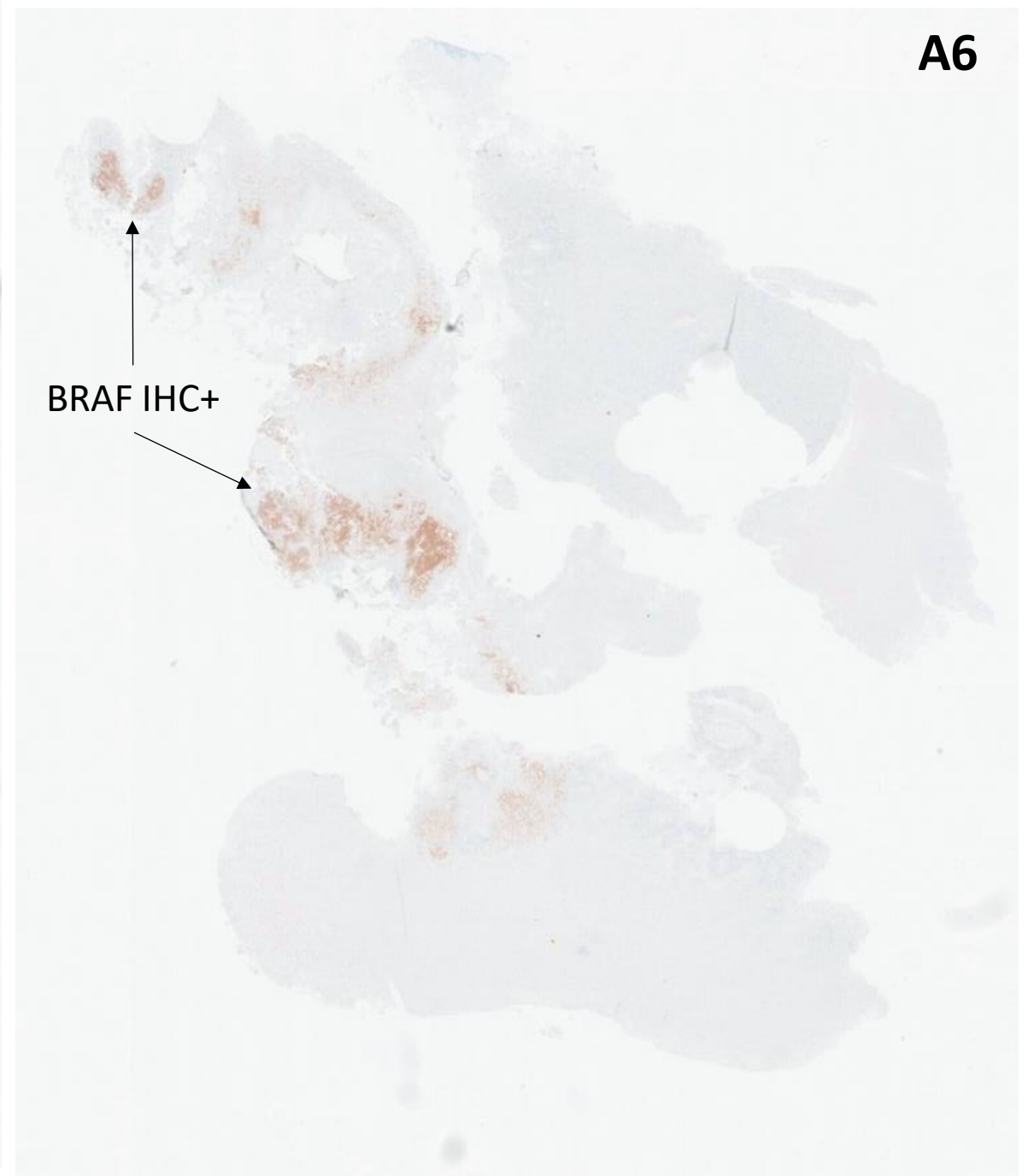
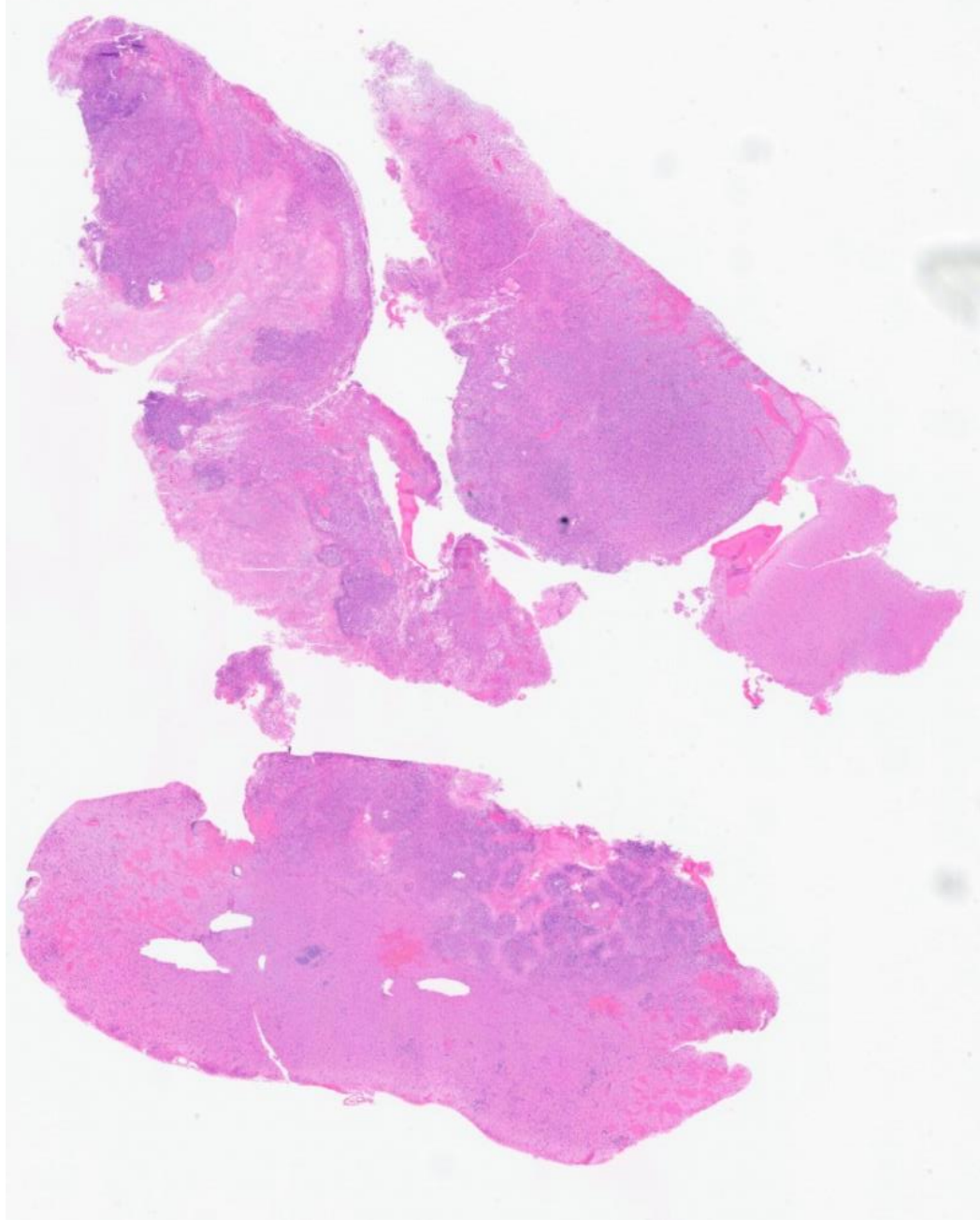
***No evidence for BRAF V600E***



## Recap: Discordant BRAF V600E results

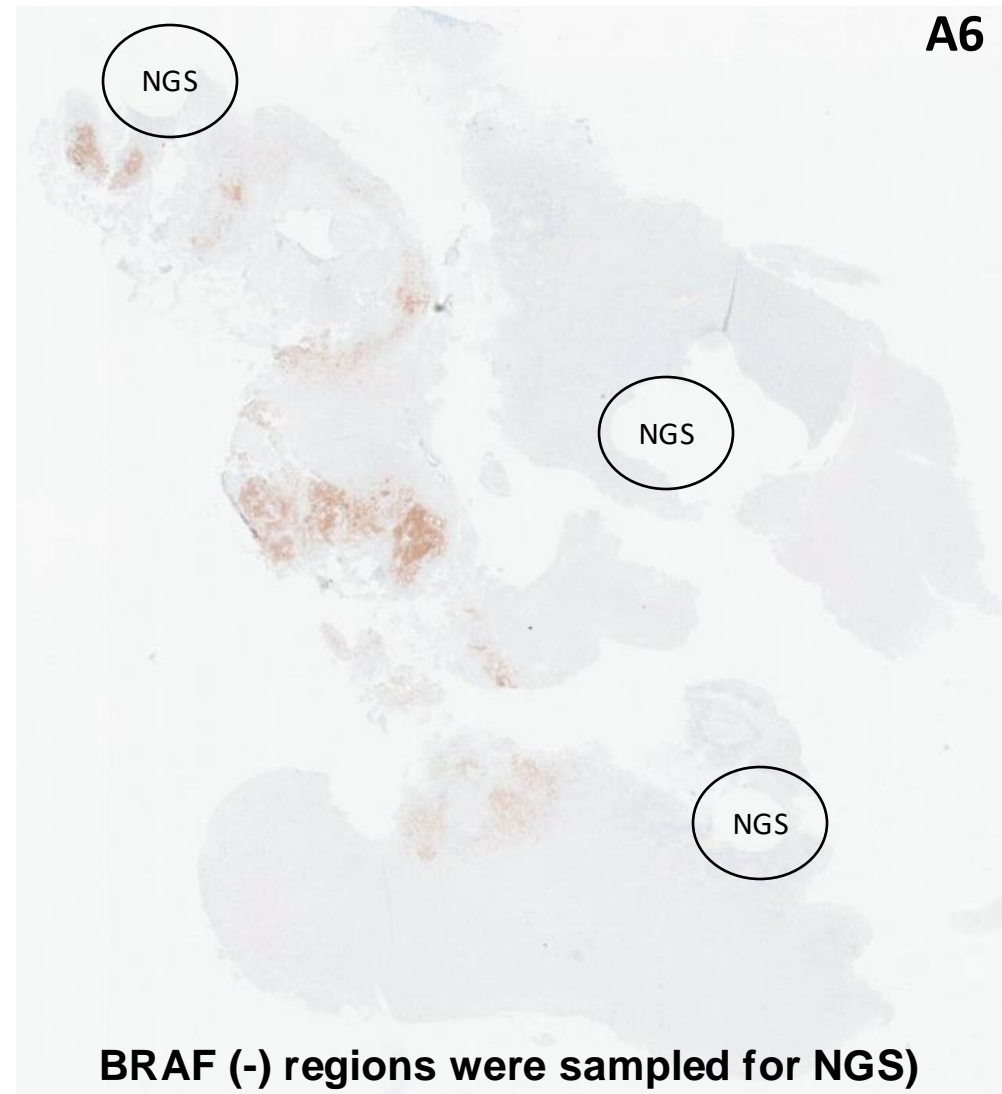
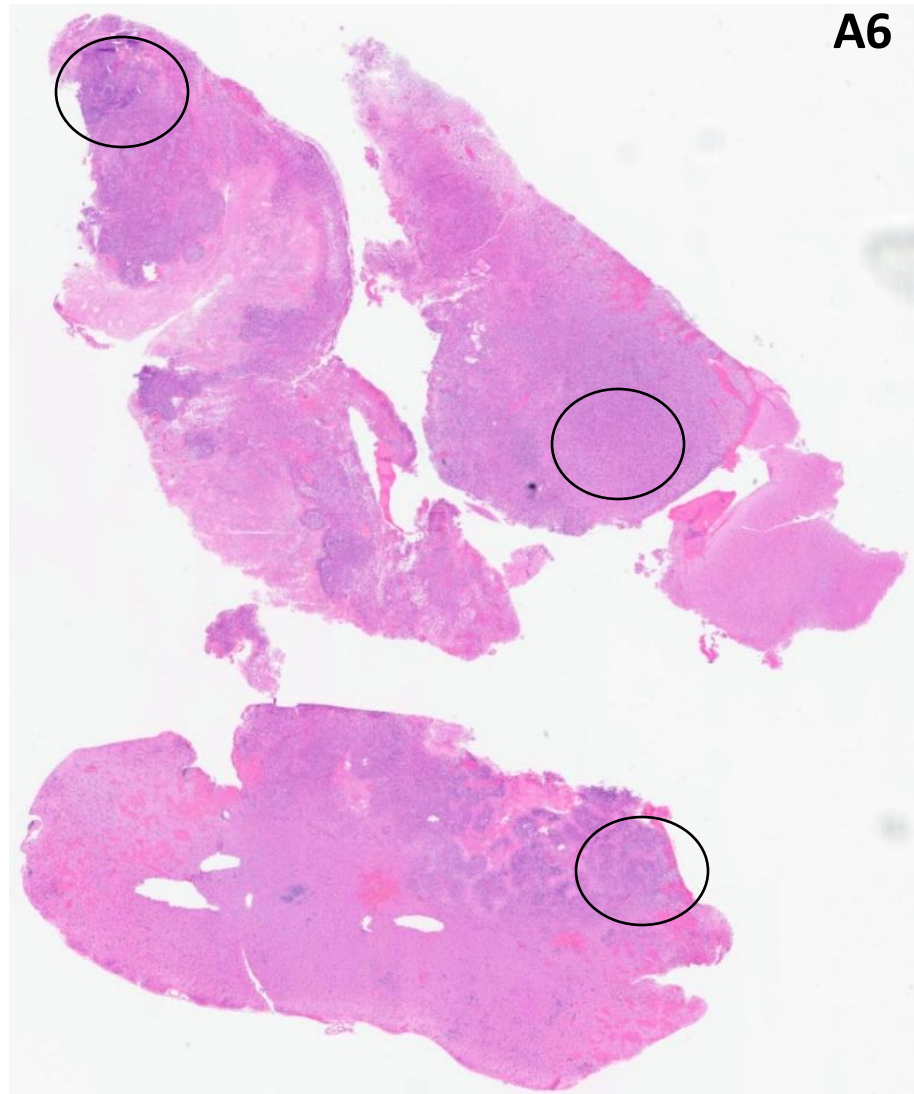
- Block A4: IHC **BRAF V600E (+)**
- Block A6: NGS CGP500 and Archer Fusion **BRAF V600E(-)**
- Next step... *Review of Histology*

**Block\_A6: Used for NGS**



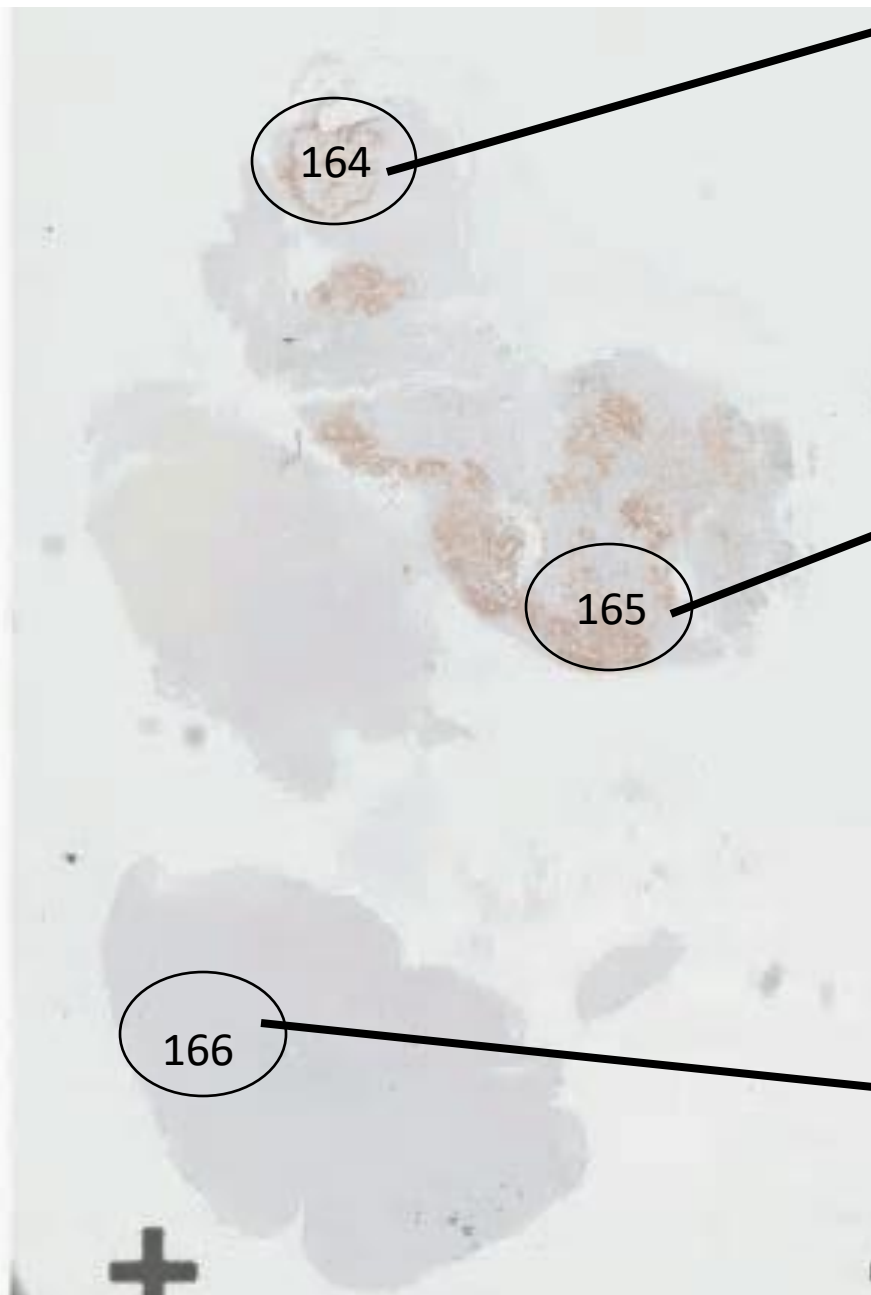
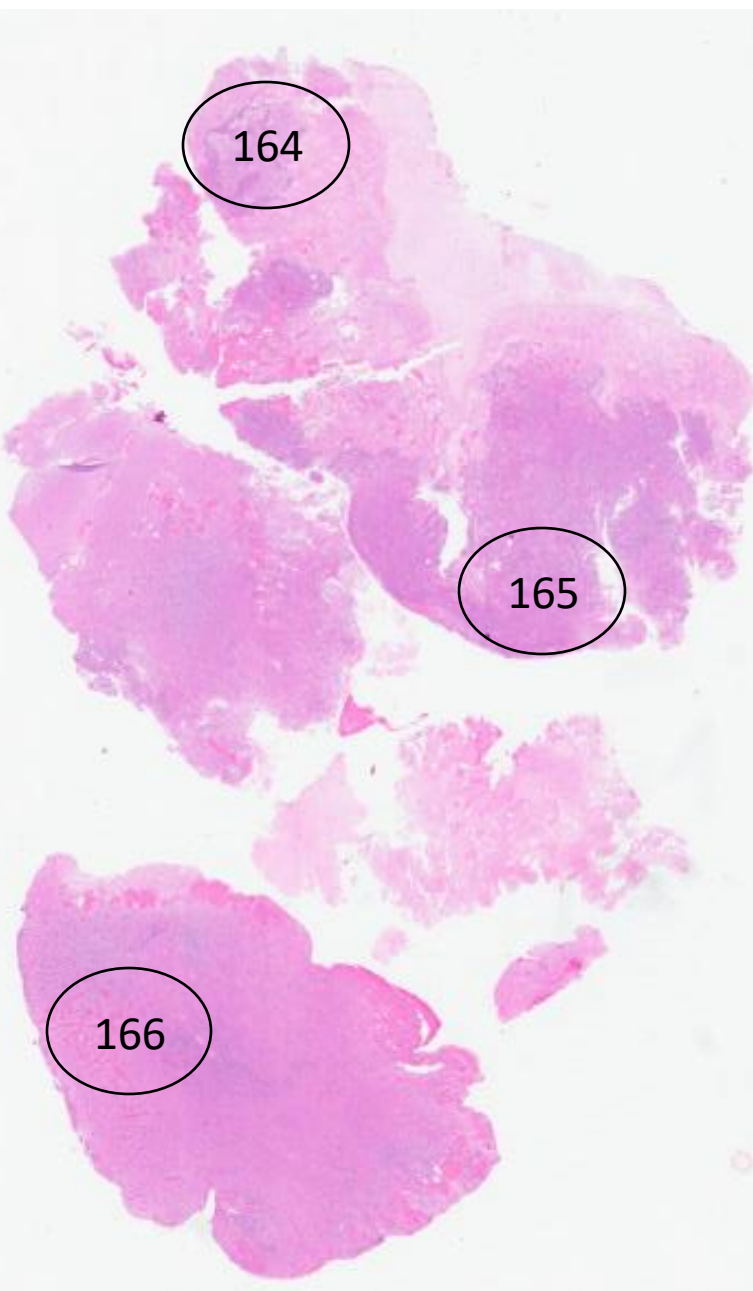
BRAF IHC+

## Block\_A6: Used for NGS



**Conventional Wisdom** “...in most patients, a single biopsy of a primary tumor captures the information necessary for therapeutic choices about the treatment of extant or presumptive metastases.”

# Block A4: Used for BRAF PCR



<b>MUTATION DETECTED IN BRAF CODON 600</b>
V600E/D
p.Val600Glu / p.Val600Asp
c.1799T>A; c.1799_1800delinsAA / c.1799_1800delinsAT; c.1799_1800delinsAC
34.4
2.9
<b>31.5</b>
<b>The assay controls have been properly amplified. The assay result is VALID.</b>

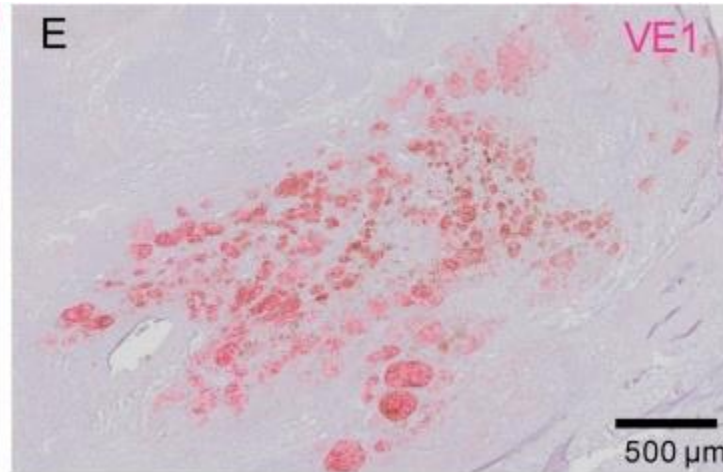
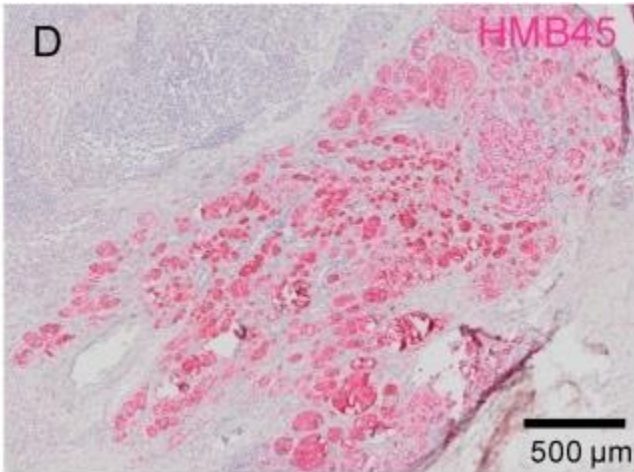
<b>MUTATION DETECTED IN BRAF CODON 600</b>
V600E/D
p.Val600Glu / p.Val600Asp
c.1799T>A; c.1799_1800delinsAA / c.1799_1800delinsAT; c.1799_1800delinsAC
34.4
2.9
<b>31.5</b>
<b>The assay controls have been properly amplified. The assay result is VALID.</b>

<b>NO MUTATION DETECTED IN BRAF CODON 600</b>
<b>31.9</b>
<b>The assay controls have been properly amplified. The assay result is VALID.</b>

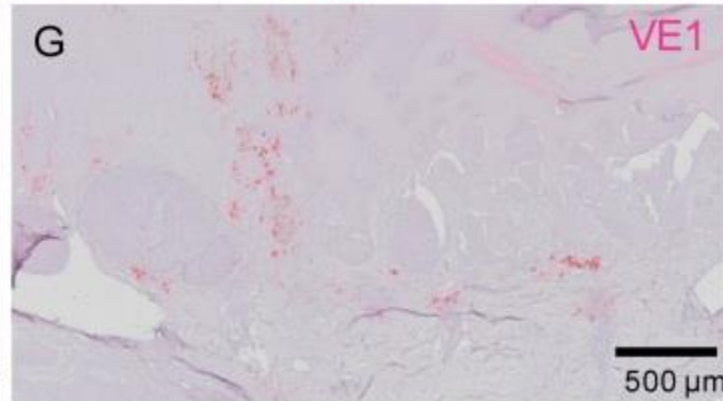
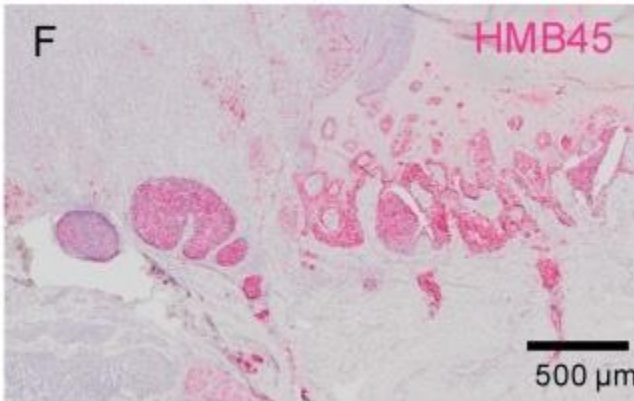
# Example of Intra-Tumor Molecular Heterogeneity in Melanoma

HMB45

VE1: BRAFV600E IHC



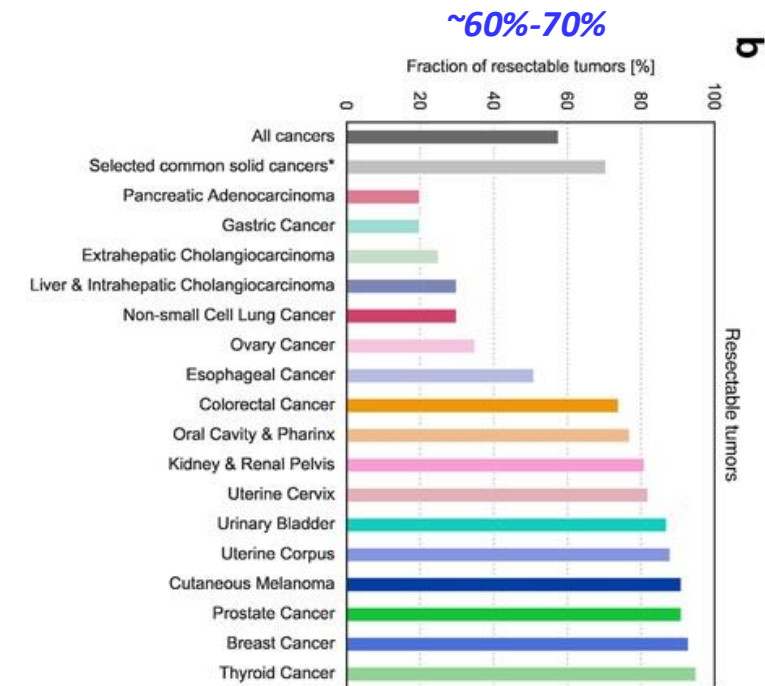
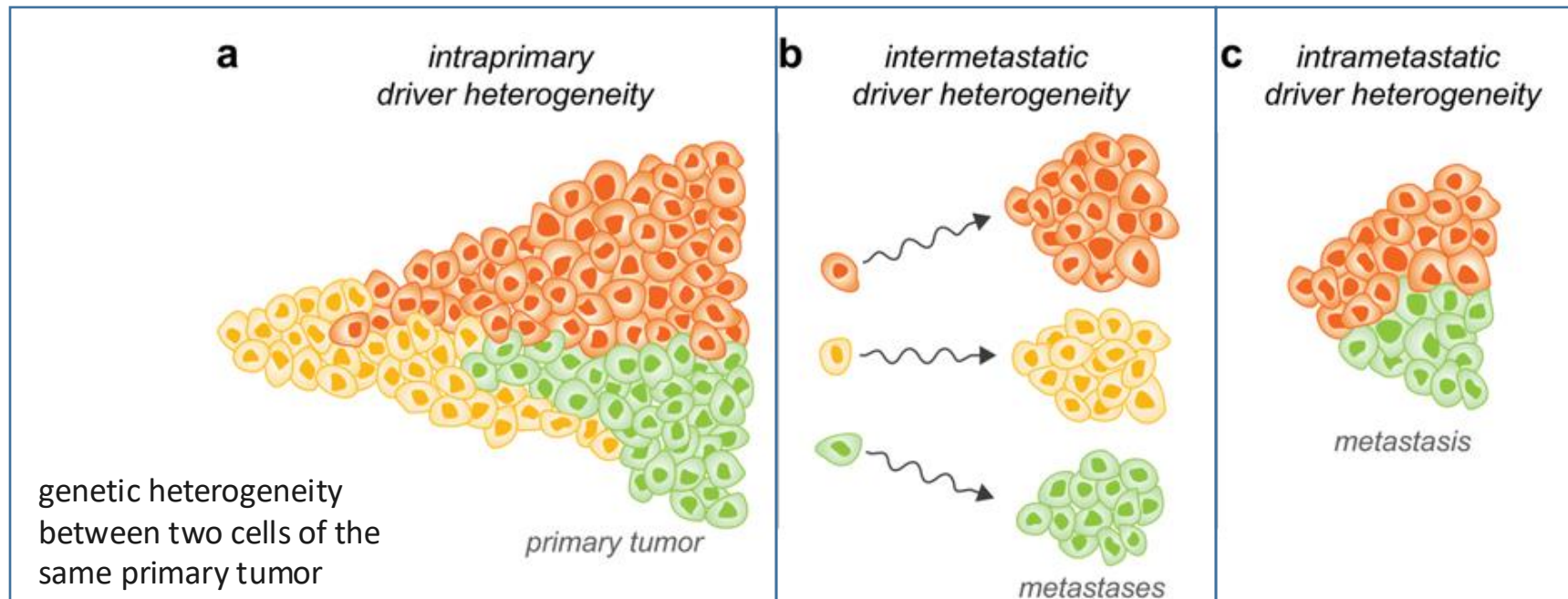
~50% of HMB45(+) melanoma cells show VE1 positivity



**None** of the melanoma cells show VE1 positivity in this area

# Tumor molecular heterogeneity

- **Genetic level:** *Every cell in every tumor is different; cancer has billions of cells*
- **Cancer subclones:** the unique genetic profiles confer varying levels of growth, invasion, and/or resistance to therapy
- **Is heterogeneity a major barrier to long term disease control ?** Metastatic or unresectable tumors



**UAB** THE UNIVERSITY OF  
ALABAMA AT BIRMINGHAM.

DEPARTMENT OF PATHOLOGY

## Case 2

*Unusual results may reveal  
underlying diseases*

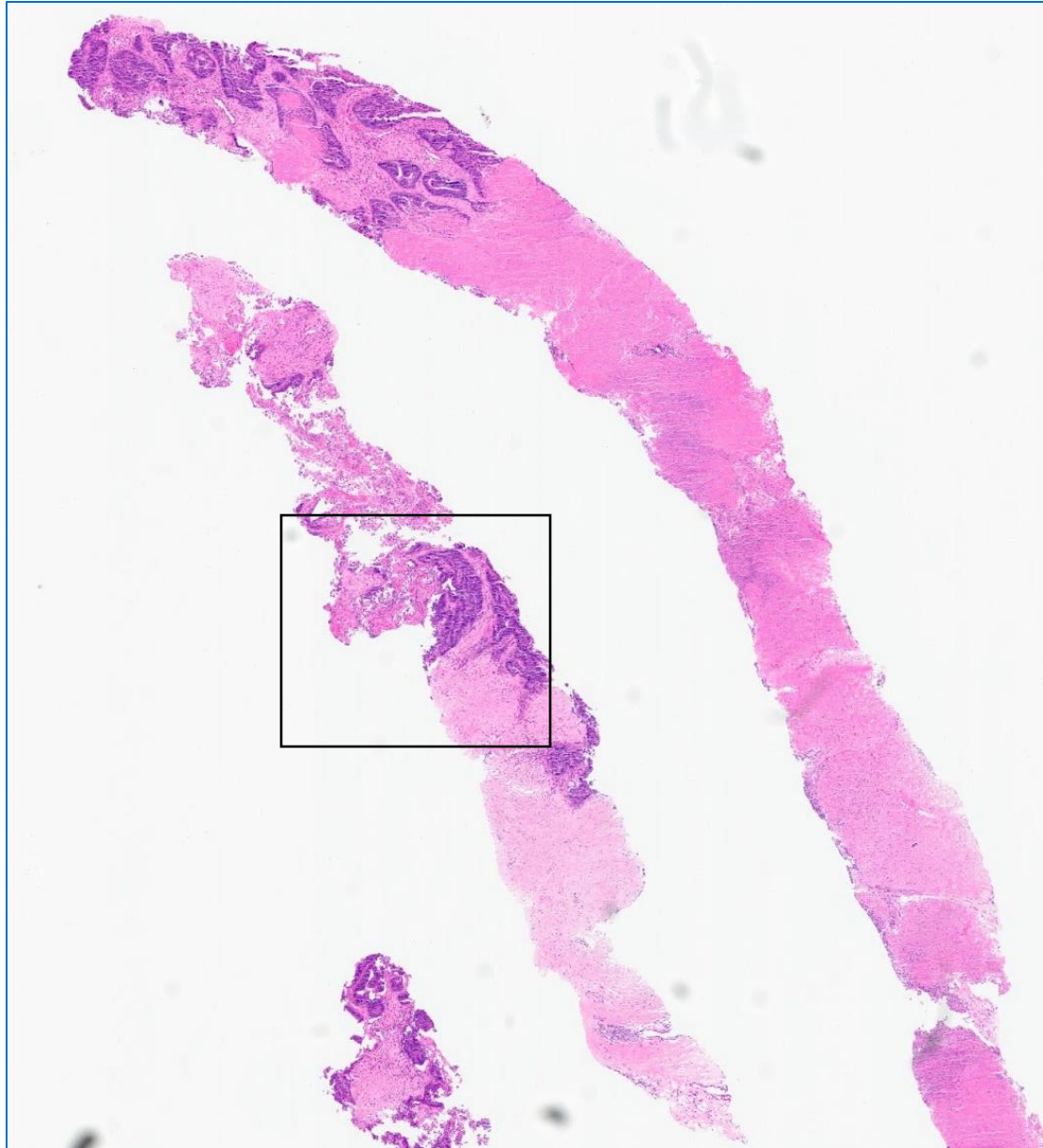


**Alyssa Lee, MD, MS  
UAB PGY-3  
AP/CP Resident**

12/27/2023

Soft tissue, pelvic mass, biopsy

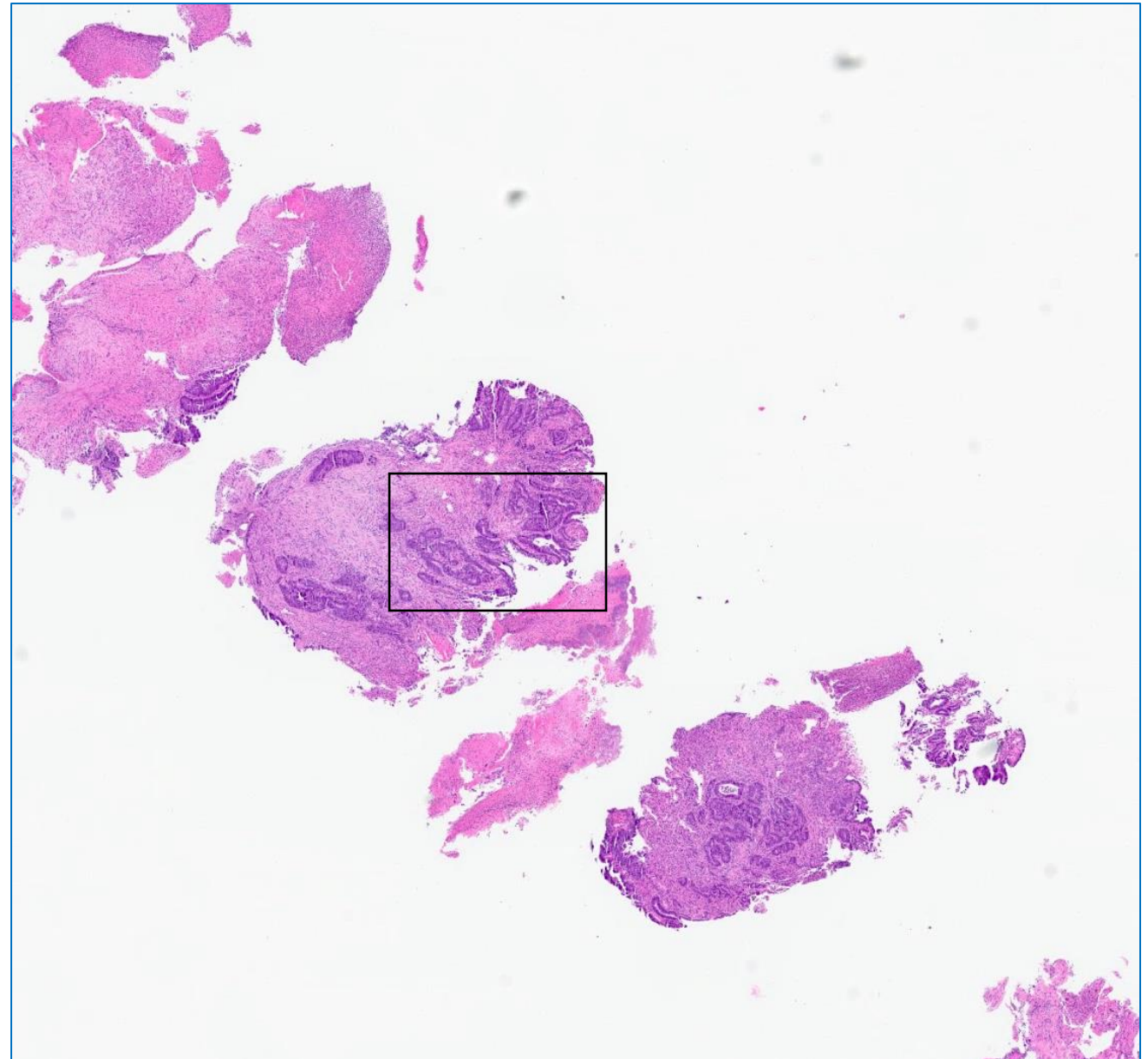
Adenocarcinoma



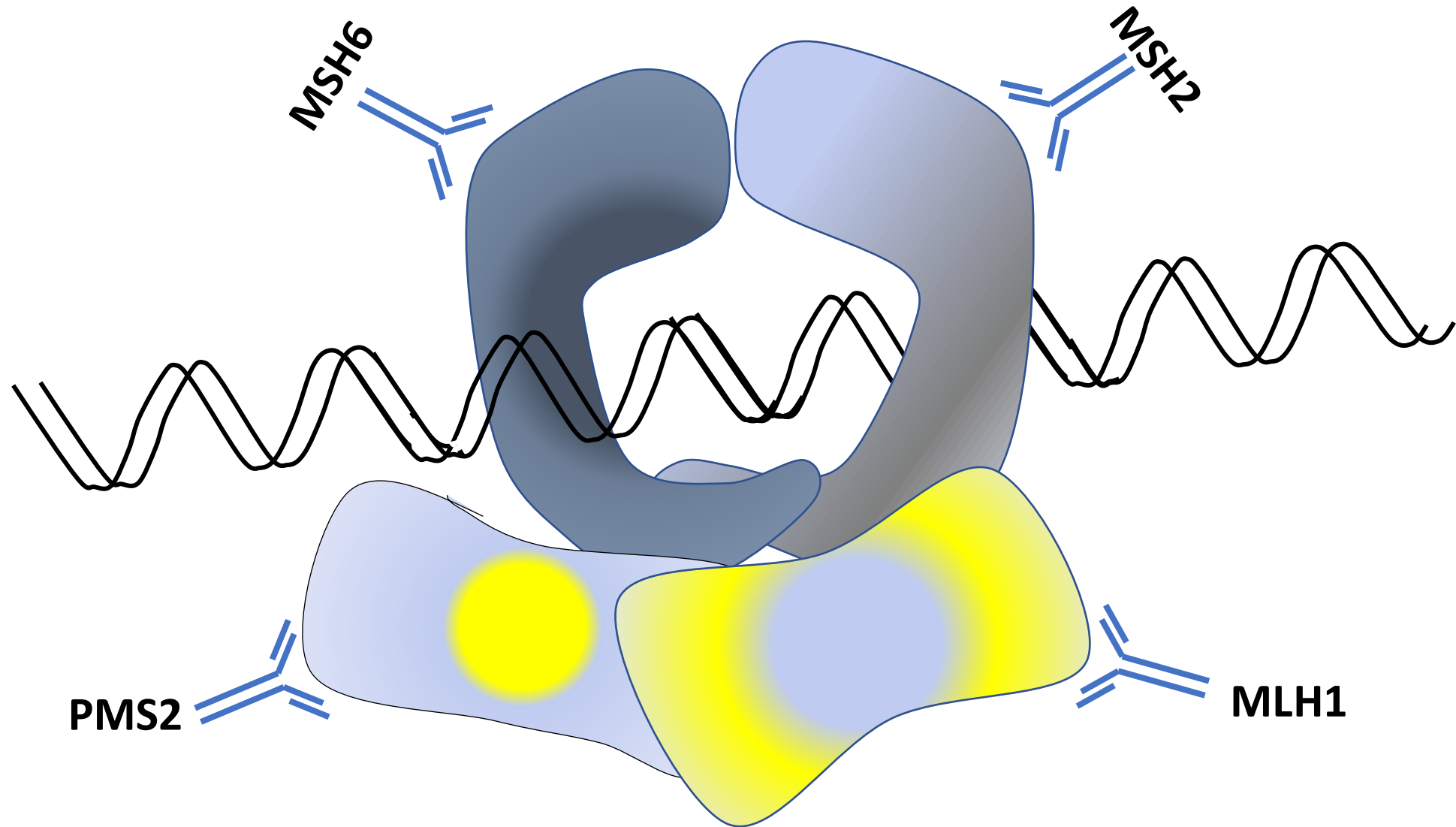
12/29/2023

Cecal mass biopsy

Adenocarcinoma

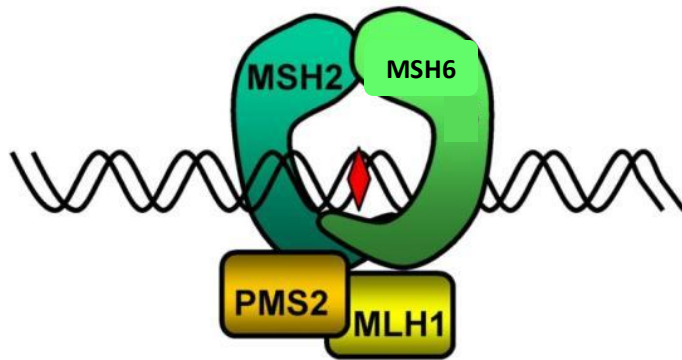


Mismatch Repair Testing (MMR) was ordered

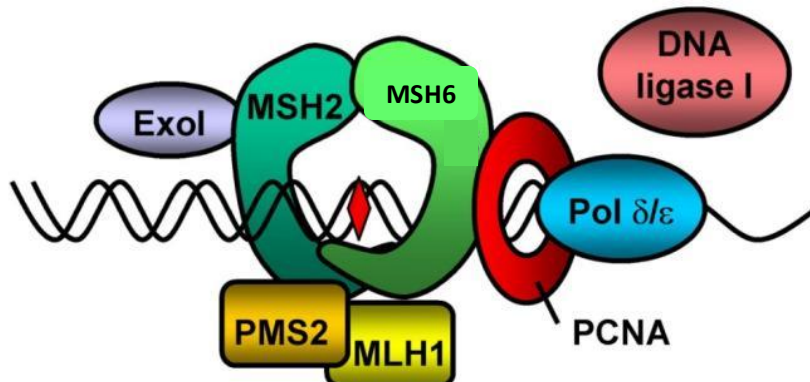


# Mismatch Repair (MMR) System

## A. Initiation



## B. Excision & resynthesis



## Genotype

### Mismatch repair genes = MMR

MLH1, MSH2, MSH6, PMS2

Proofread and repair mismatches during replication (pMMR)

*“Fixes mistakes” that happen naturally when cells divide*

## Phenotype

### Loss of function of MMR genes leads to accumulation of mutations in genome (dMMR)

Some mutations occur in critical genes becoming the initiating event in a patient's cancer

*Defective MMR = Microsatellite Instability Phenotype (MSI)*

# Why is MMR/MSI testing performed?

## Characterization of Cancer



1. Prognostic Stratification



2. Lynch Syndrome Screening



3. Predictive Value

## Clinical Practice Guidelines



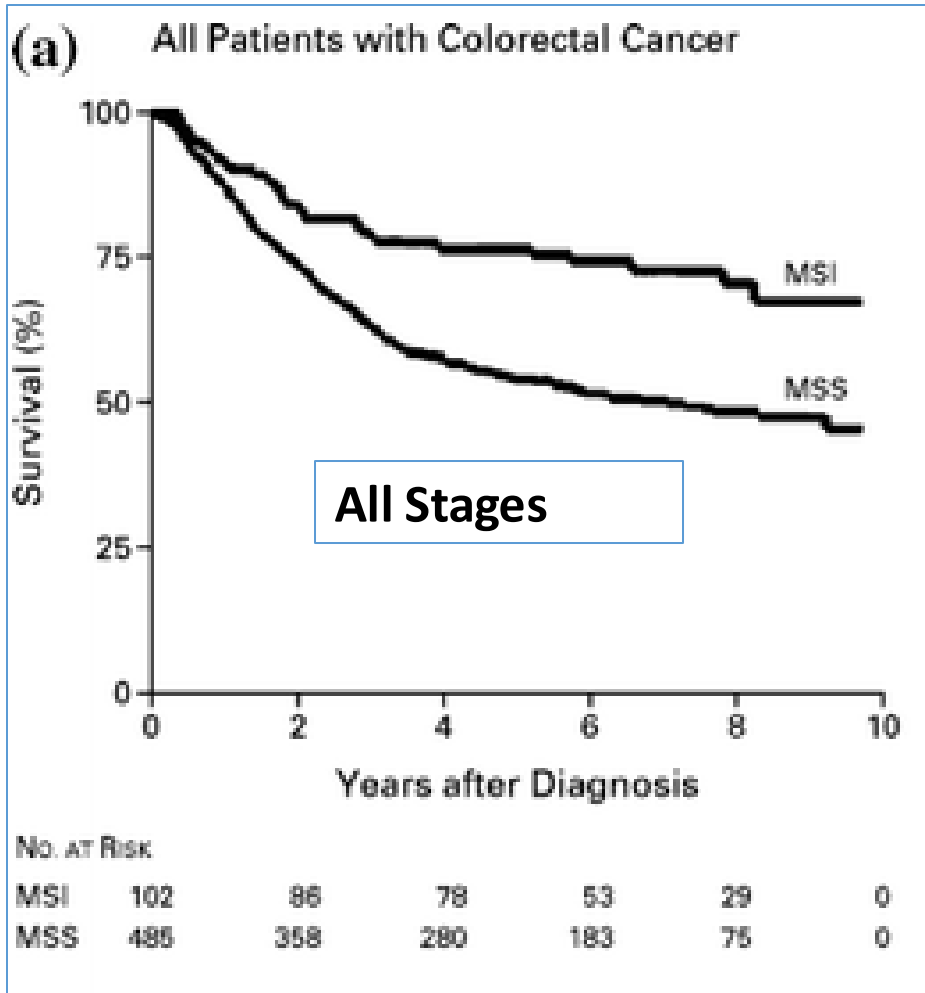
“Tumor screening for MMR deficiency is appropriate for all **CRC and endometrial cancers...**”



“Clinicians should order MMR status testing in patients with **colorectal cancer** for identification of patients at high risk for Lynch syndrome and/or prognostic stratification”

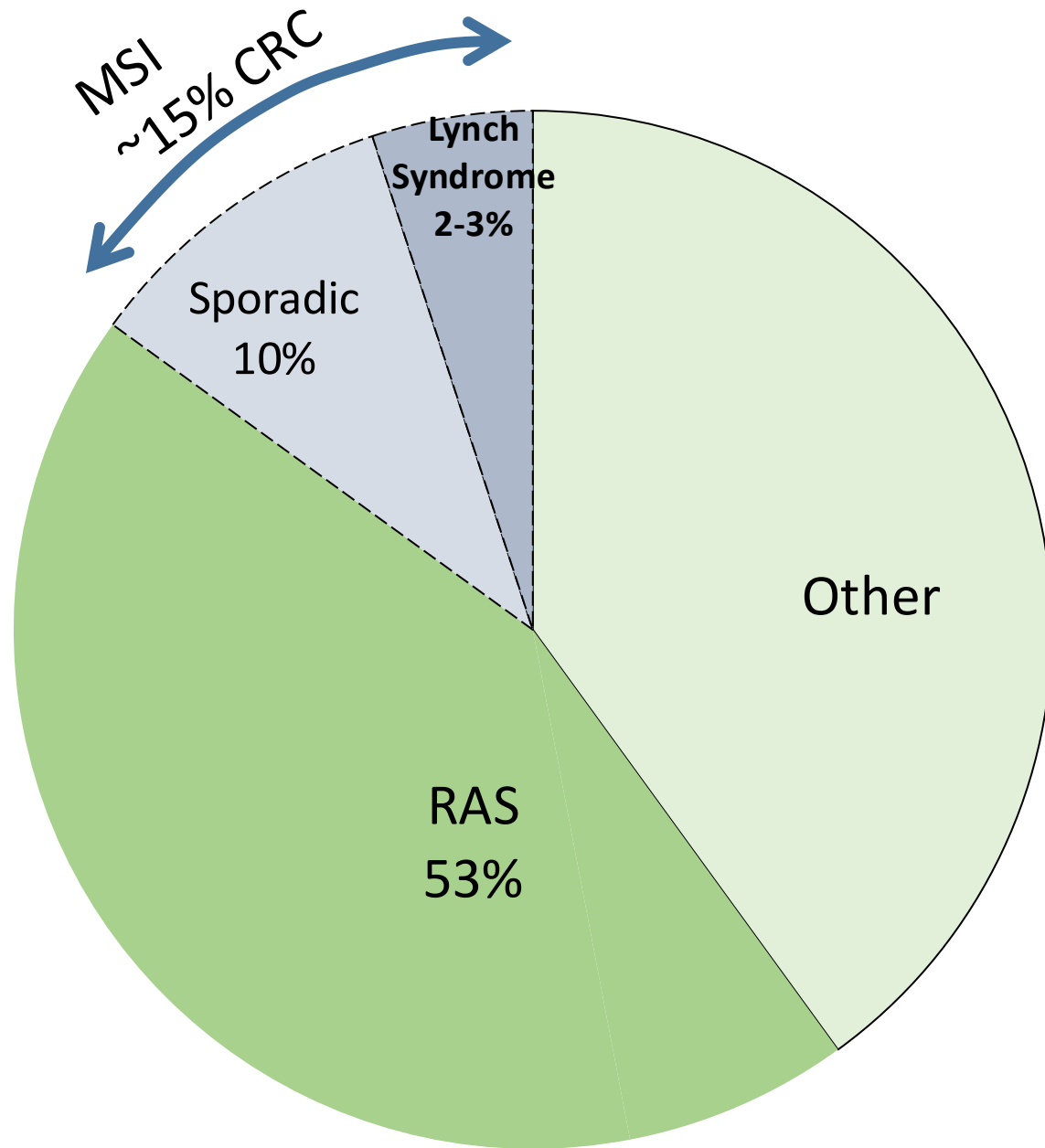
Does cancer with **defective MMR (MSI)** *have better/worse prognosis ?*

# MSI has better prognosis



Patients with MSI have a more favorable prognosis:  
31 studies reporting survival on 12,782 patients with MSI tumors demonstrate a favorable prognosis

MSI tumors have a decreased likelihood to metastasize



MSI in Colon Cancer can be...

### Inherited

- Lynch Syndrome
- A defective MMR gene is **inherited from one parent**
- Most common genetic syndrome for predisposition to cancer

### Sporadic

- MMR genes are inactivate due to **acquired genetic changes**

# Lynch Syndrome (LS)

*(Hereditary Nonpolyposis Colorectal Cancer)*

Inherited predisposition to developing cancer

Genetic defect in DNA MMR genes

*MLH1, MSH2, MSH6, PMS2, EPCAM*

Types of Cancers

*Colorectal, endometrial (most common)*

2-3% of CRC occurs in LS patients

CRC presents at an earlier age

*40's versus 60's*

Cancer	Lifetime Risk, LS
Colon	28-80%
Endometrial	30-50%
Small intestine	4-7%
Stomach	2-13%
Ovarian	3-13%
Hepatobiliary tract	2%
Upper GU	1-12%
Brain (GBM)	1-4%
Skin	2-6%

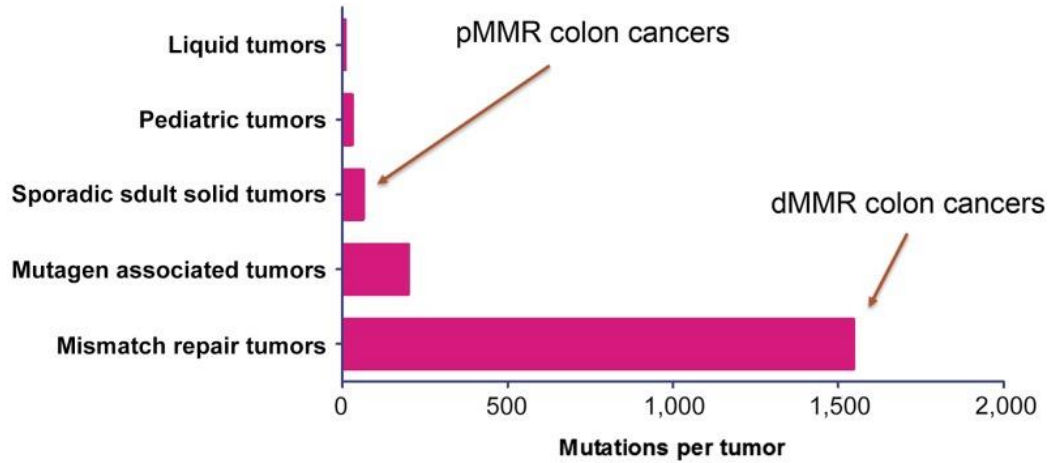
# Predictive: 5-FU ADJUVANT THERAPY in CRC

- **Reduced** response to [5-FU](#) based chemotherapy in dMMR tumors
- 5-FU is used in adjuvant therapy following surgery in Stage-II/III CRC
- MSI CRC have a good prognosis and may not benefit from adjuvant chemotherapy (NCCN)

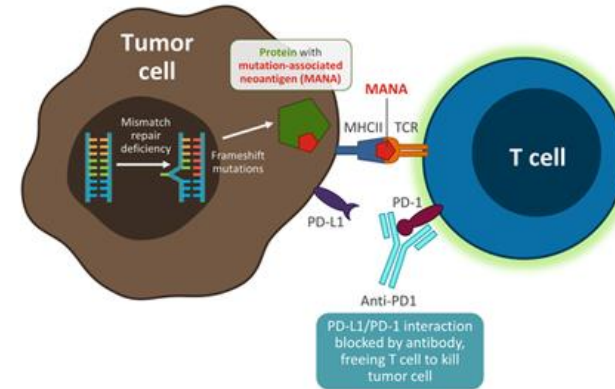
G. Hutchins, K. Southward, K. Handley, L. Magill, C. Beaumont, J. Stahlschmidt, S. Richman, P. Chambers, M. Seymour, D. Kerr, R. Gray, P. Quirke. Value of mismatch repair, KRAS, and BRAF mutations in predicting recurrence and benefits from chemotherapy in colorectal cancer. *J. Clin. Oncol.*, 29 (10) (2011), pp. 1261-1270.

National Comprehensive Cancer Network (NCCN) Clinical Practice Guidelines in Oncology, Version 2.2015 Colon Cancer, COL-D, 2015. Version 2.2015, 34 (2015).

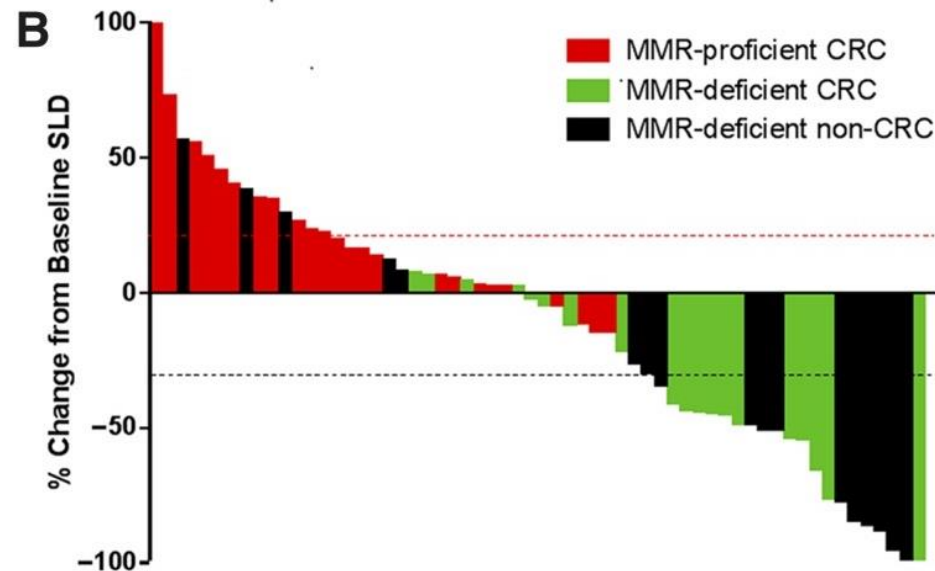
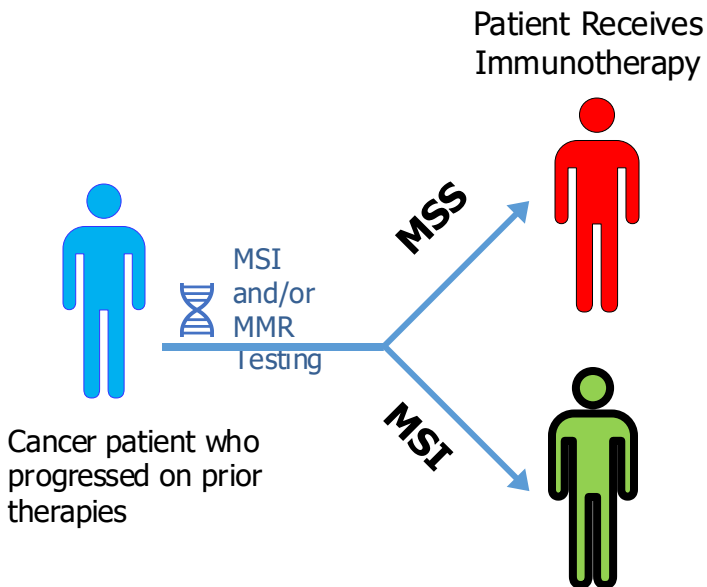
# MMR/MSI predicts best response to PD-1 inhibition



## MSI Status and Immunologic Response



Dudley J, et al. *Clin Cancer Res.* 2016;22:813-820.



**KEYTRUDA**  
(pembrolizumab) for injection 50mg

MERCK

TEST FOR MSI OR MMR TO SEE IF KEYTRUDA COULD BE RIGHT FOR YOU

Getting tested for MSI or MMR status can help determine if KEYTRUDA could be an appropriate treatment for you or someone you care about.

Test if you have any of these cancers:

- Colorectal
- Endometrial
- Biliary
- Bladder
- Breast
- Esophageal
- Gastric or gastroesophageal junction
- Pancreatic
- Prostate
- Renal cell
- Reproductive adenocarcinoma
- Sarcoma
- Small cell lung
- Small intestine
- Thyroid
- Other advanced solid tumors

**KEYTRUDA IS THE FIRST FDA-APPROVED IMMUNOTHERAPY BASED ON A BIOMARKER, REGARDLESS OF TUMOR TYPE**

KEYTRUDA may be used in adults and children to treat:

- cancer that has spread or cannot be removed by surgery (advanced cancer), and
- has progressed following treatment, and you have no satisfactory treatment options, or
- you have colon or rectal cancer, and you have received chemotherapy with fluoropyrimidine, oxaliplatin, and irinotecan but it did not work or is no longer working.

It is not known if KEYTRUDA is safe and effective in children with MSI-H cancers of the brain or spinal cord (central nervous system cancers).

**OPDIVO**  
(nivolumab)

Bristol-Myers Squibb

### INDICATION

For People 12 Years of Age and Older Whose dMMR or MSI-H CRC Has Spread to Other Parts of the Body (Metastatic) and Who Have Tried Chemotherapy With a Fluoropyrimidine, Oxaliplatin, and Irinotecan and It Did Not Work or Is No Longer Working

OPDIVO® (nivolumab) is a prescription medicine used to treat adults and children 12 years of age and older who have colorectal cancer (a type of colon or rectal cancer), and who:

- Have colorectal cancer that has spread to other parts of the body (metastatic); **AND**
- Have a tumor that is mismatch repair deficient (dMMR) or microsatellite instability-high (MSI-H); **AND**

- Have tried chemotherapy with a fluoropyrimidine, oxaliplatin, and irinotecan, and it did not work or is no longer working.

OPDIVO was approved based on response rate and how long patients' responses lasted. There is ongoing evaluation of clinical benefit of OPDIVO for this use.

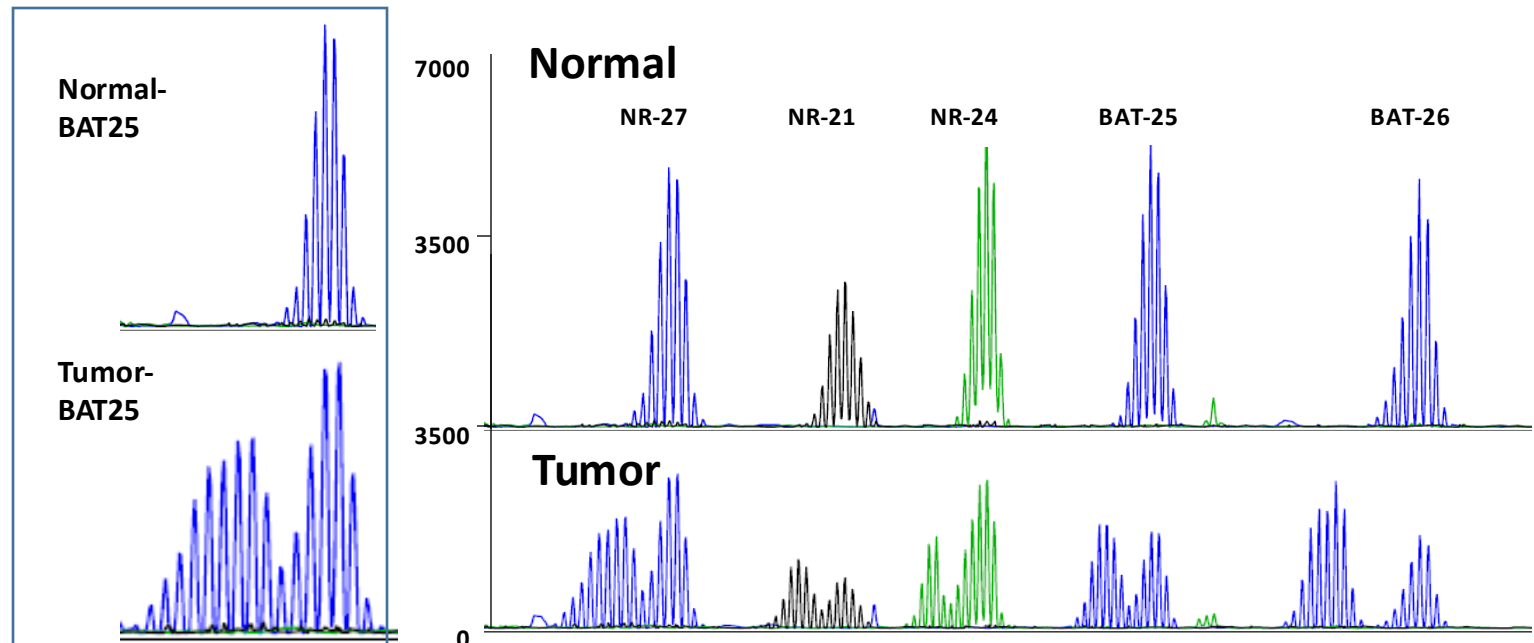
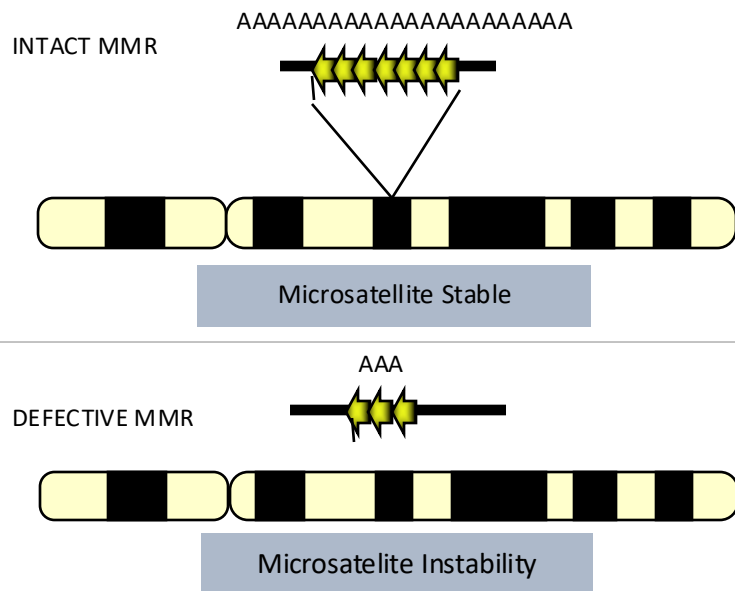
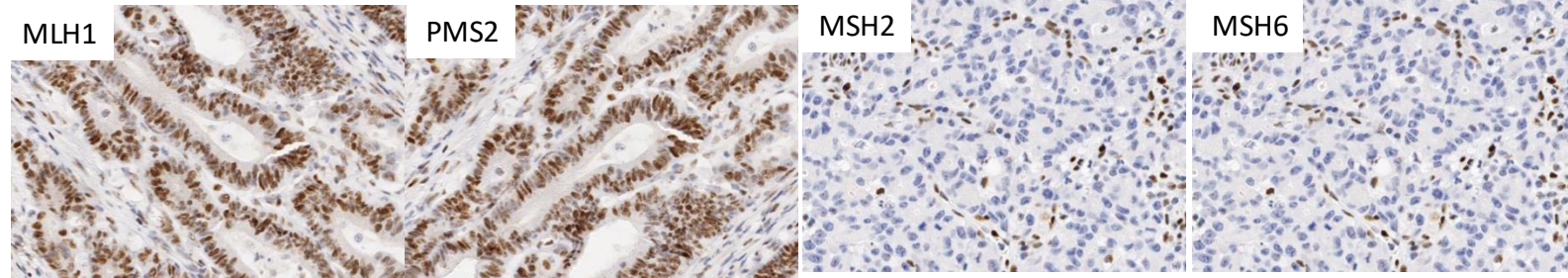
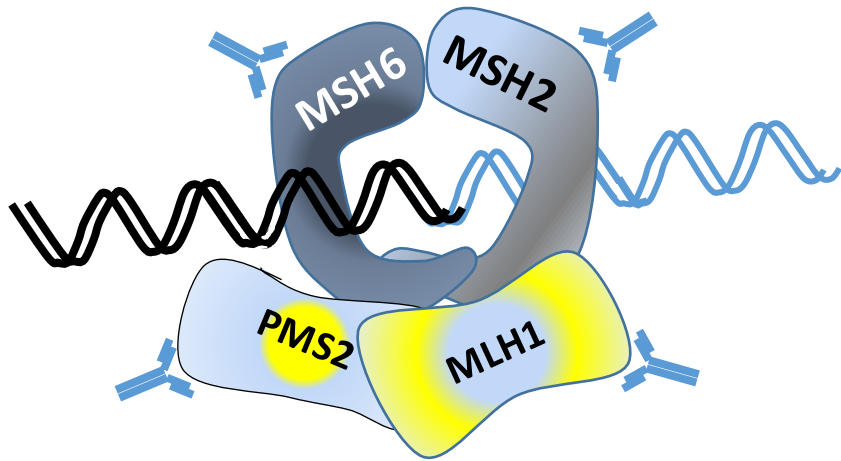
It is not known if OPDIVO is safe and effective in children less than 12 years of age with MSI-H or dMMR metastatic colorectal cancer.

Lee V, *Oncologist.* 21(10):1200-1211, 2016.

Le, *NEJM.* 372:2509-2520, 2015

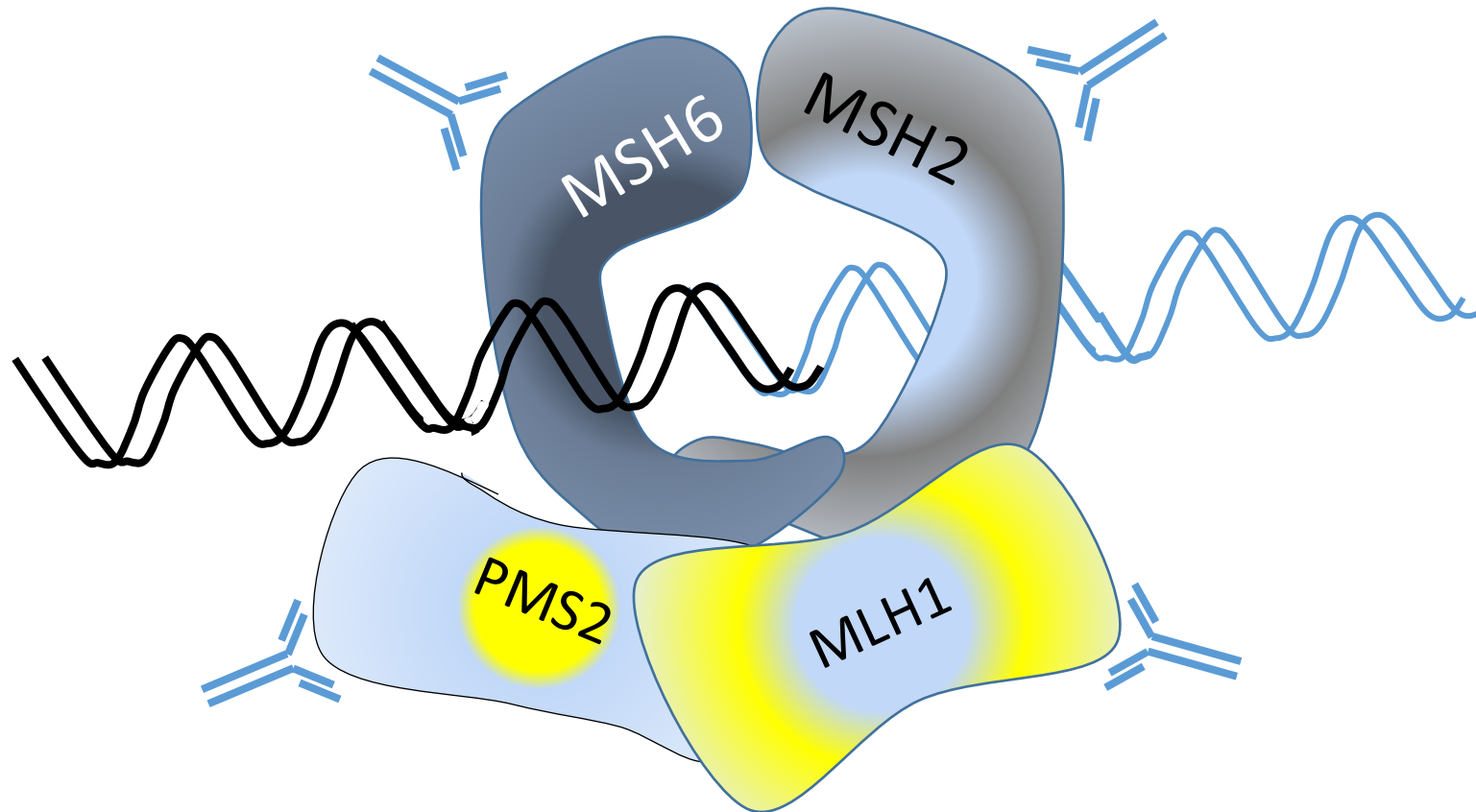
Le, *Science.* 357(6349):409-413, 2017

# MMR/MSI Testing : IHC or MSI

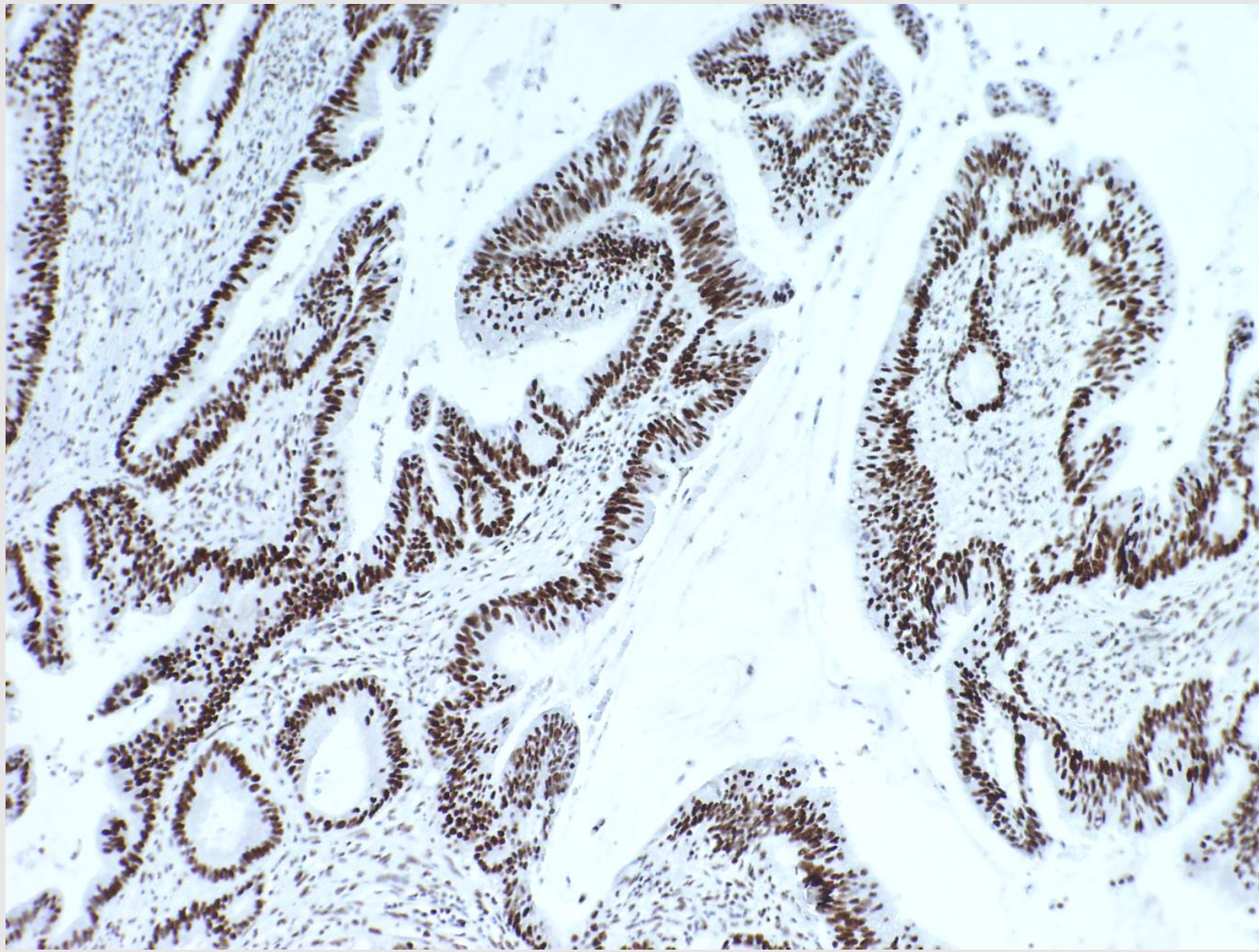


# MMR Immunohistochemistry

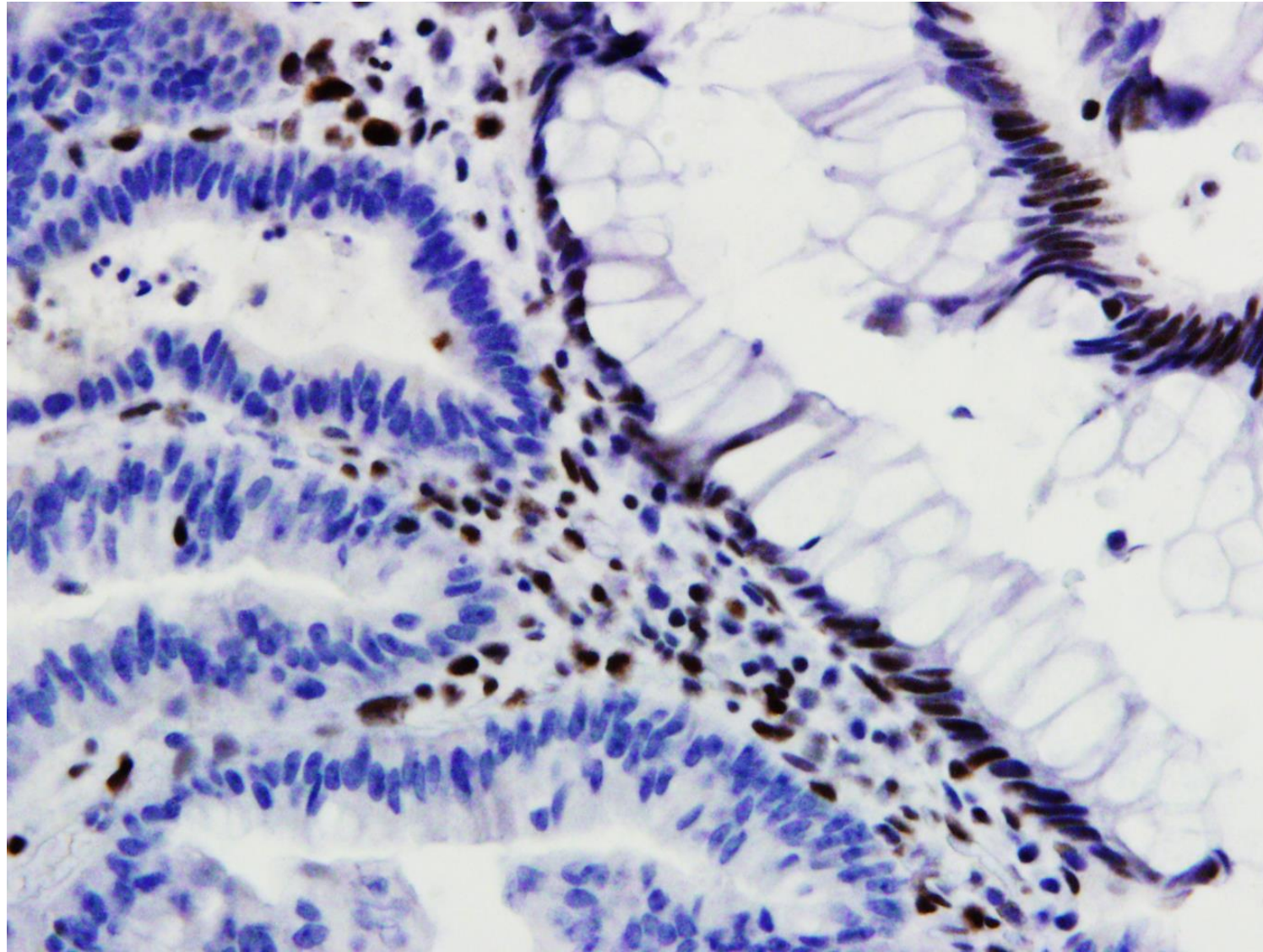
---



# Positive Staining (MLH1): tumor & normal

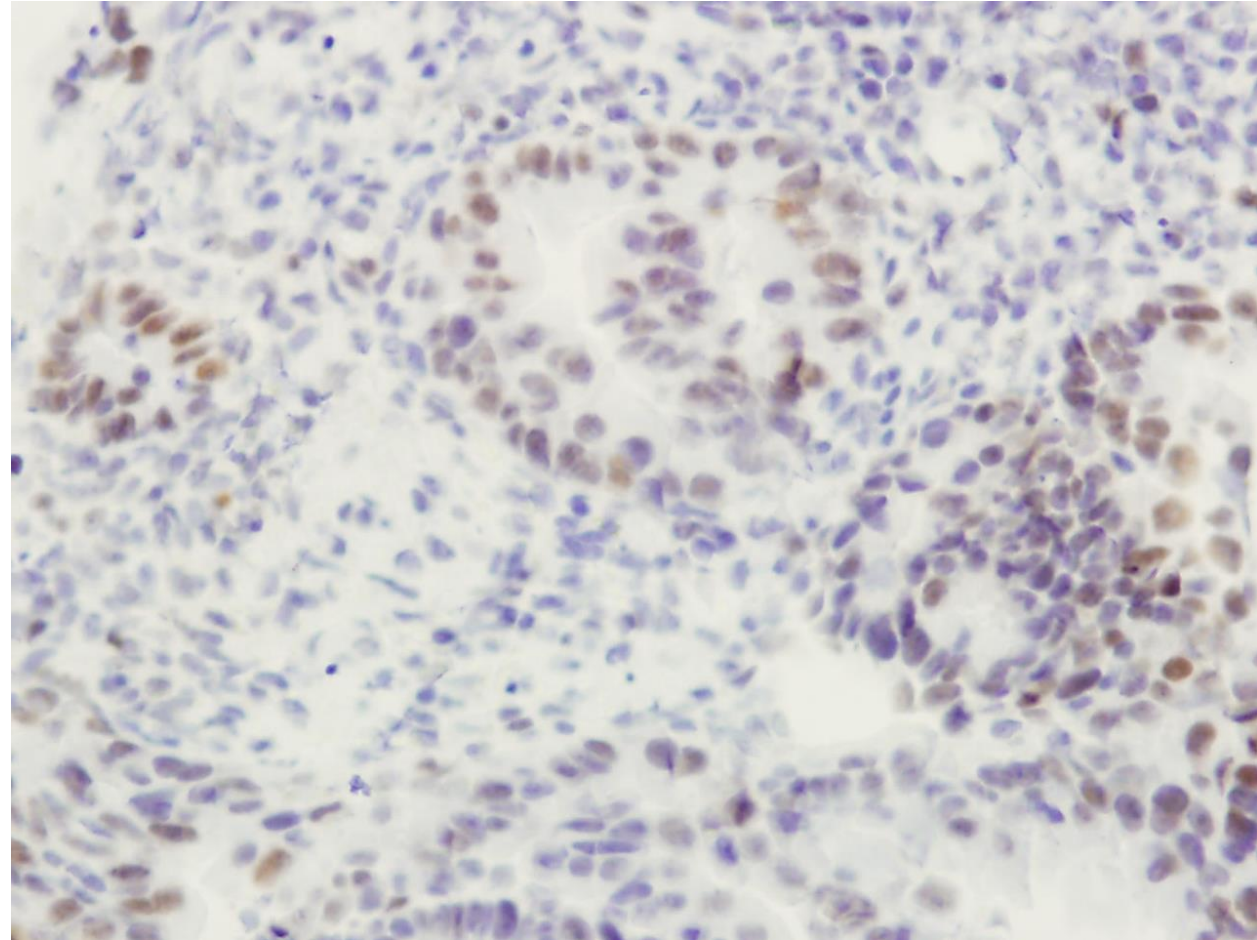
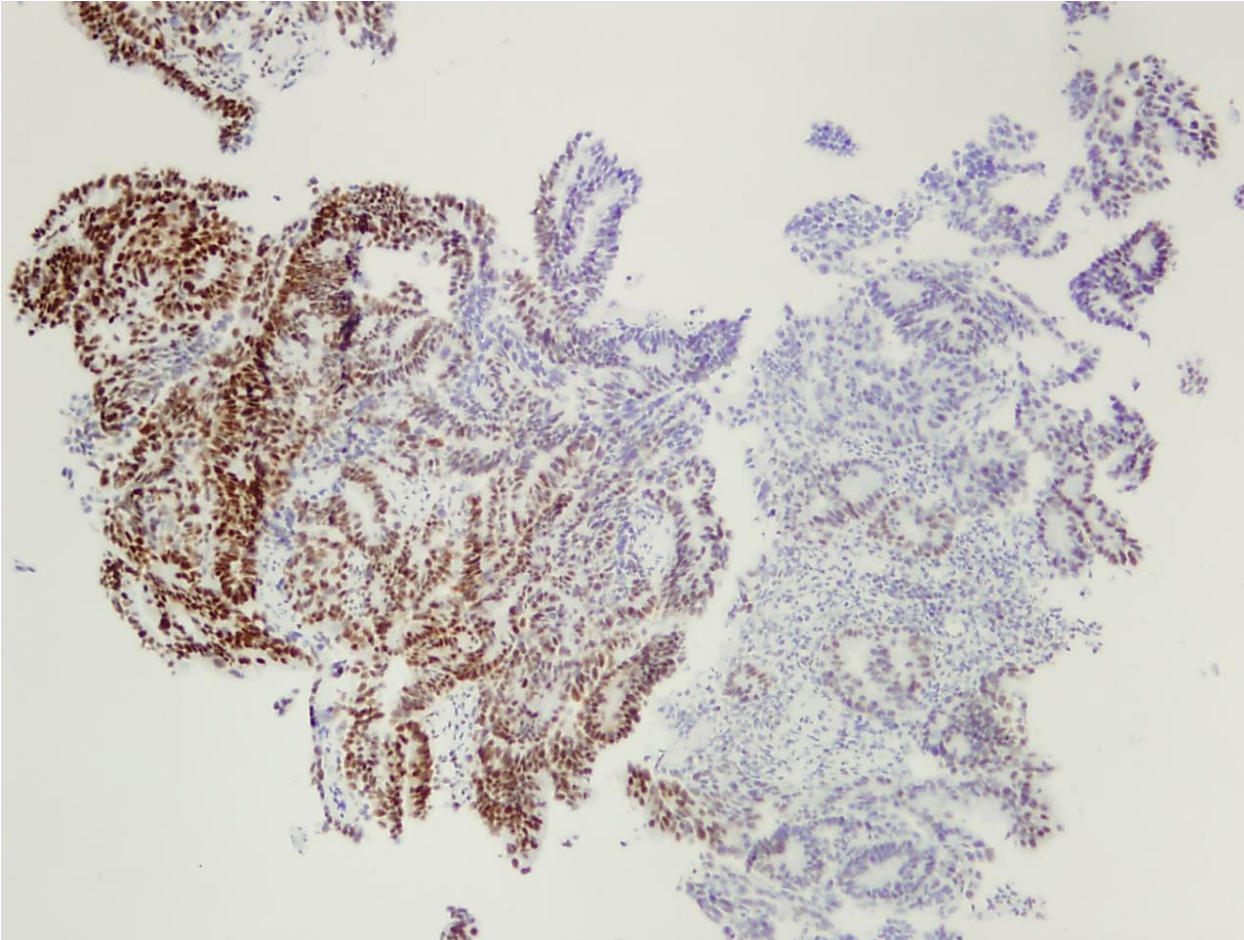


# Negative Staining (MLH1) in tumor cells




# Challenges with IHC:

Faint nuclear staining is interpreted as positive

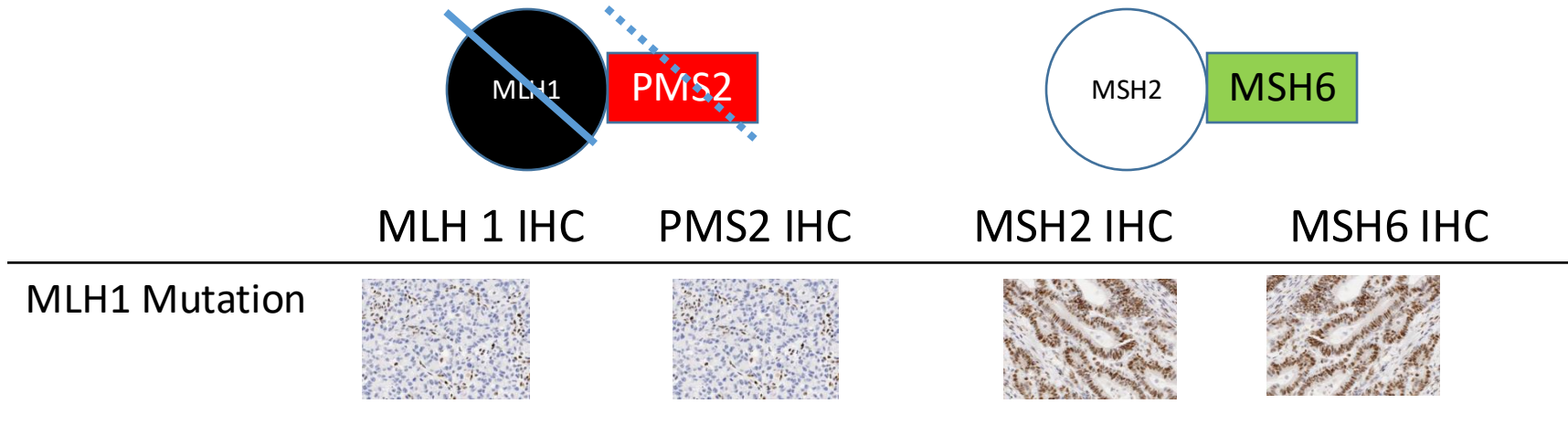


1

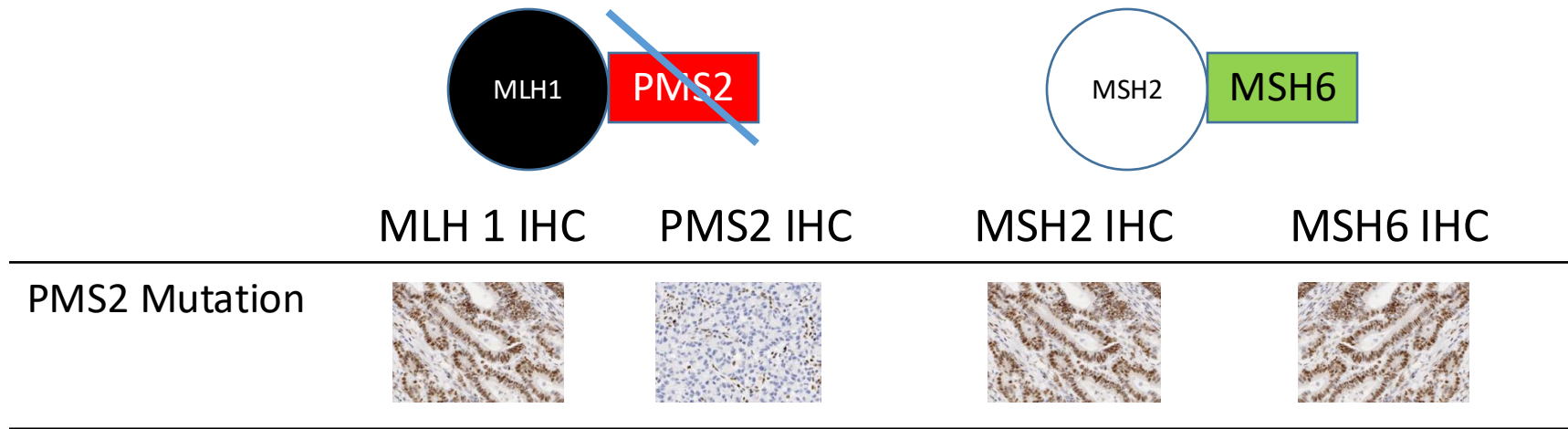


Most common pattern (85%)  
pMMR staining

2




PMS2 binds MLH1 and depends upon MLH1 for stability  
PMS2 degraded when MLH1 is not expressed  
**dMMR staining**




Very Rare to observed isolated PMS2  
Consistent with Lynch Syndrome  
**dMMR staining**

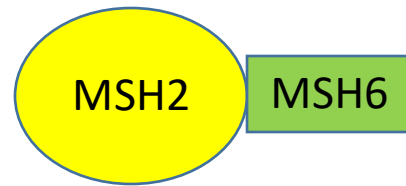

4



MSH6 binds MSH2 and depends upon MSH2 for stability  
Consistent with Lynch Syndrome  
**dMMR staining**



MSH6 isolated loss  
Consistent with Lynch Syndrome  
dMMR staining



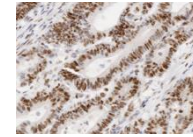
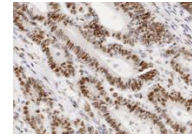
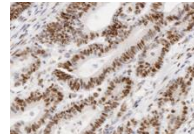
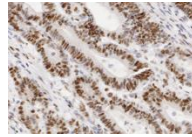
MLH 1 IHC

PMS2 IHC

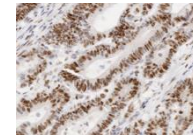
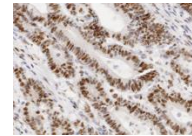
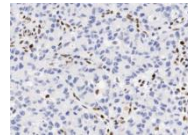
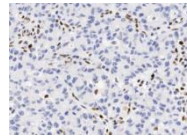
MSH2 IHC

MSH6 IHC

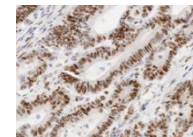
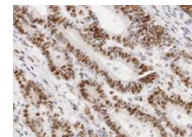
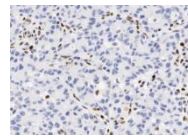
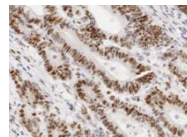
1. No Mutation



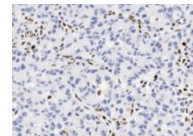
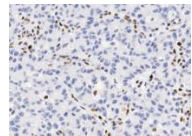
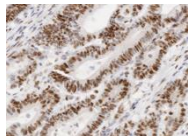
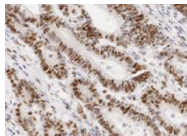
2. MLH1 Mutation



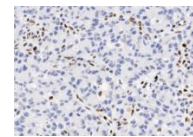
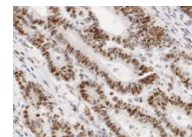
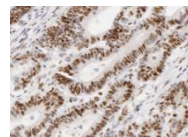
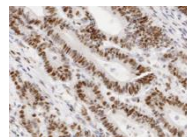
3. PMS2 Mutation\*



4. MSH2 Mutation\*



5. MSH6 Mutation\*



pMMR staining  
85%


dMMR staining  
15%

\* *Likely Lynch Syndrome*


# MSI TESTING: What are microsatellites

- Microsatellites are short repeats of DNA
  - Unit is 1 – 6 nucleotides
  - Unit Repeated 5 – 50 times
  - Distributed throughout the genome
- Microsatellites change size when MMR is defective
- Analysis of microsatellites are highly effective approach to assess the MMR system

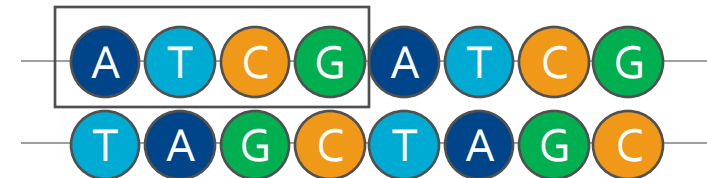
*Mononucleotide  
Microsatellite*



*Dinucleotide  
Microsatellite*



*Tetranucleotide  
Microsatellite*



# Repetitive regions are more likely to have mismatches

- pMMR: Cells with proficient mismatch repair machinery correct mistakes and maintain stability (MSS)
- dMMR: Cells with deficient mismatch repair acquire mistakes leading to microsatellite instability (MSI)

## Microsatellite Stable

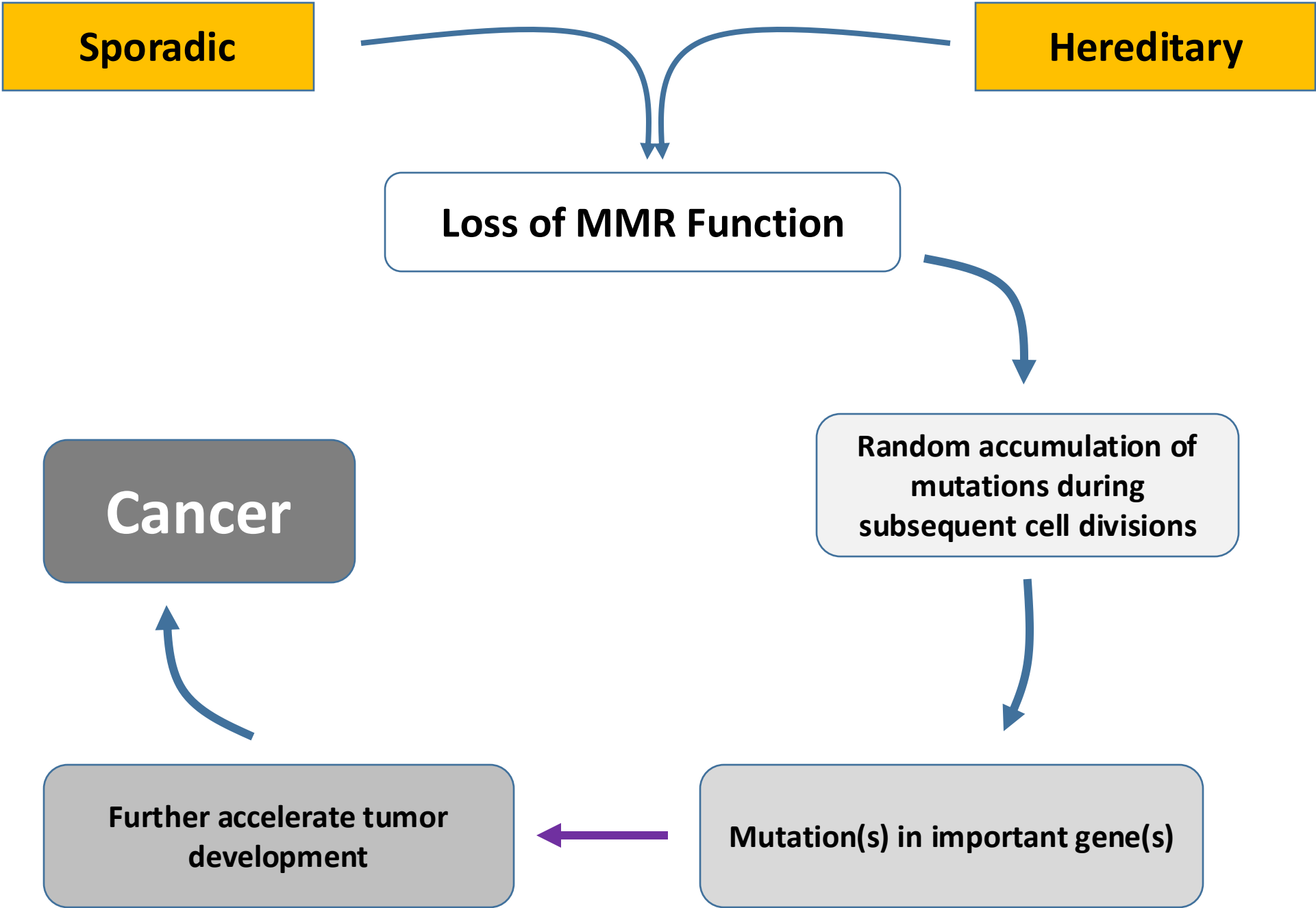


**pMMR**  
"crampons"  
No DNA errors

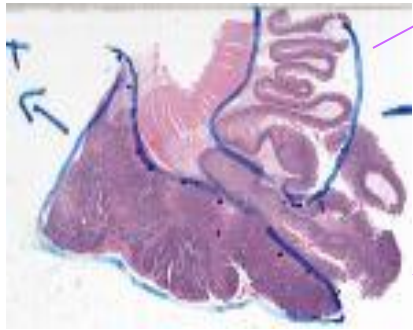
## Microsatellite Instability



**dMMR**  
"Slip and fall"  
DNA mutations



# Microsatellites are sensitive markers of defective MMR function



**Normal  
tissue**

**Tumor  
tissue**

Flanking PCR Primers

→ ←  
GCTTTTAGGAAAAAAAAAAAAAAAAAAAAAAAAAGTCCTTAG  
CGAAAATCCTTTTTTTTTTTTTTTTTTTTTTTTTCAGGAATC  
24 A's

→ ←  
GCTTTTAGGAAAAAAAAAAAAAAAAAAAAAAAAAGTCCTTAG  
CGAAAATCCTTTTTTTTTTTTTTTTTTTTTTTTTCAGGAATC  
15 A's

**Readout:** the size in nucleotides of the PCR products using electrophoresis  
Example of MSI

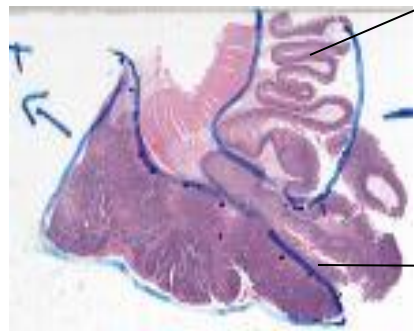# Testing of Mononucleotide Microsatellites

Examine 5 mononucleotide microsatellite markers

Two tissue samples are tested: Normal and Tumor

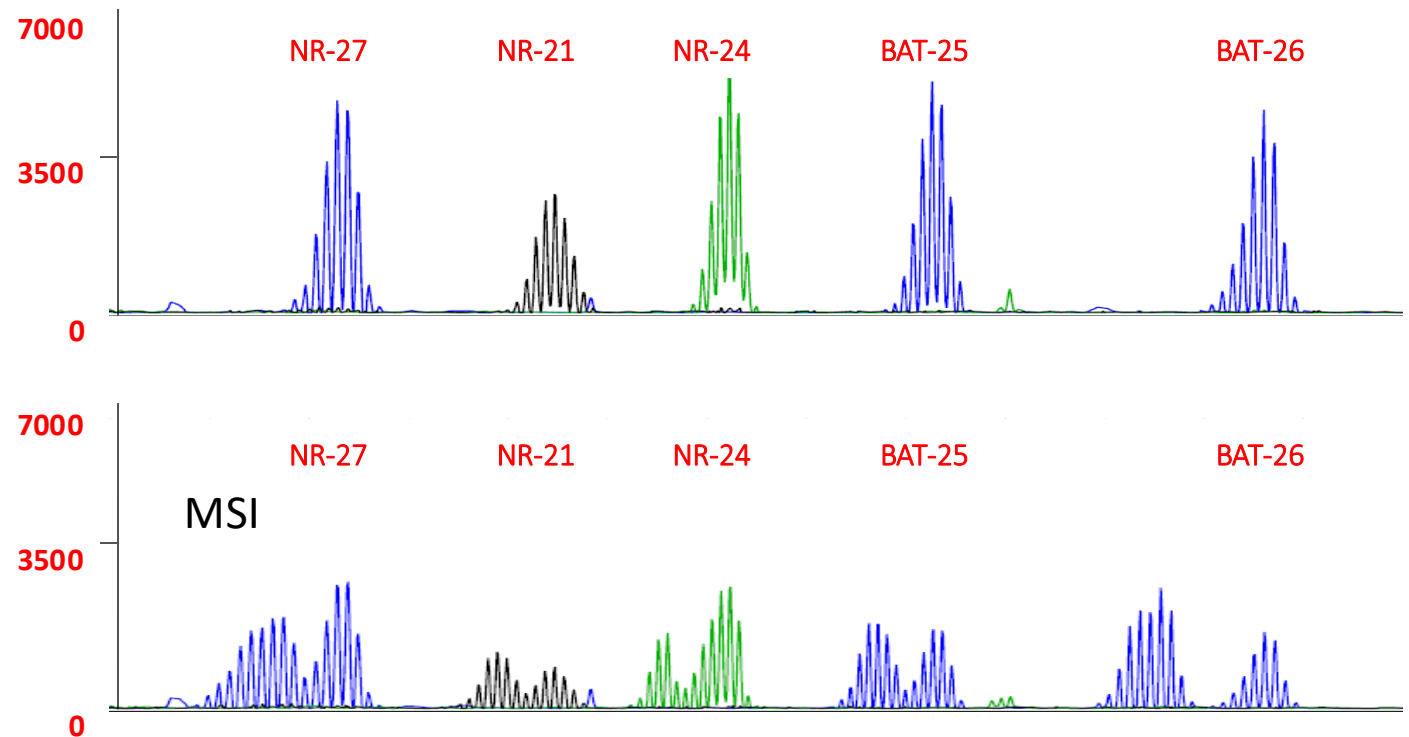
Compare the lengths of the tumor and normal microsatellites

**MSI in 2 or more microsatellite loci= MSI-H**



Normal

Tumor



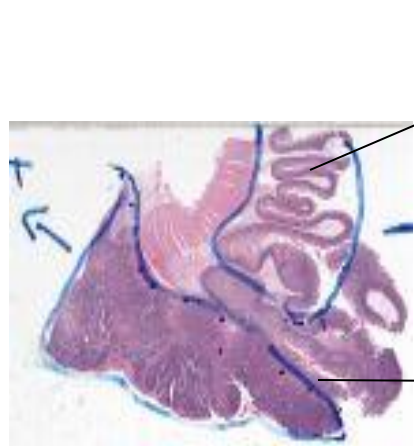
# Testing of Mononucleotide Microsatellites

Examine 5 mononucleotide microsatellite markers

Two tissue samples are tested: Normal and Tumor

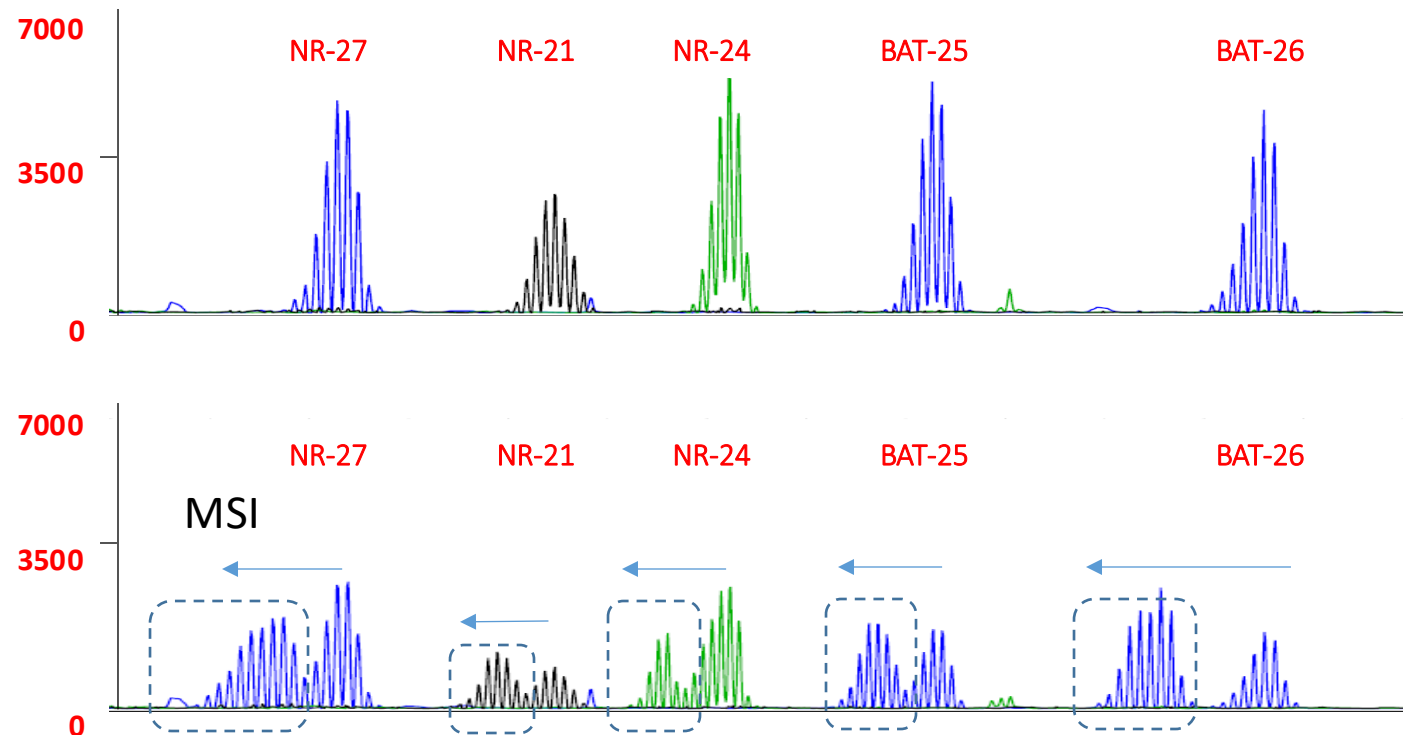
Compare the lengths of the tumor and normal microsatellites

**MSI in 2 or more microsatellite loci= MSI-H**

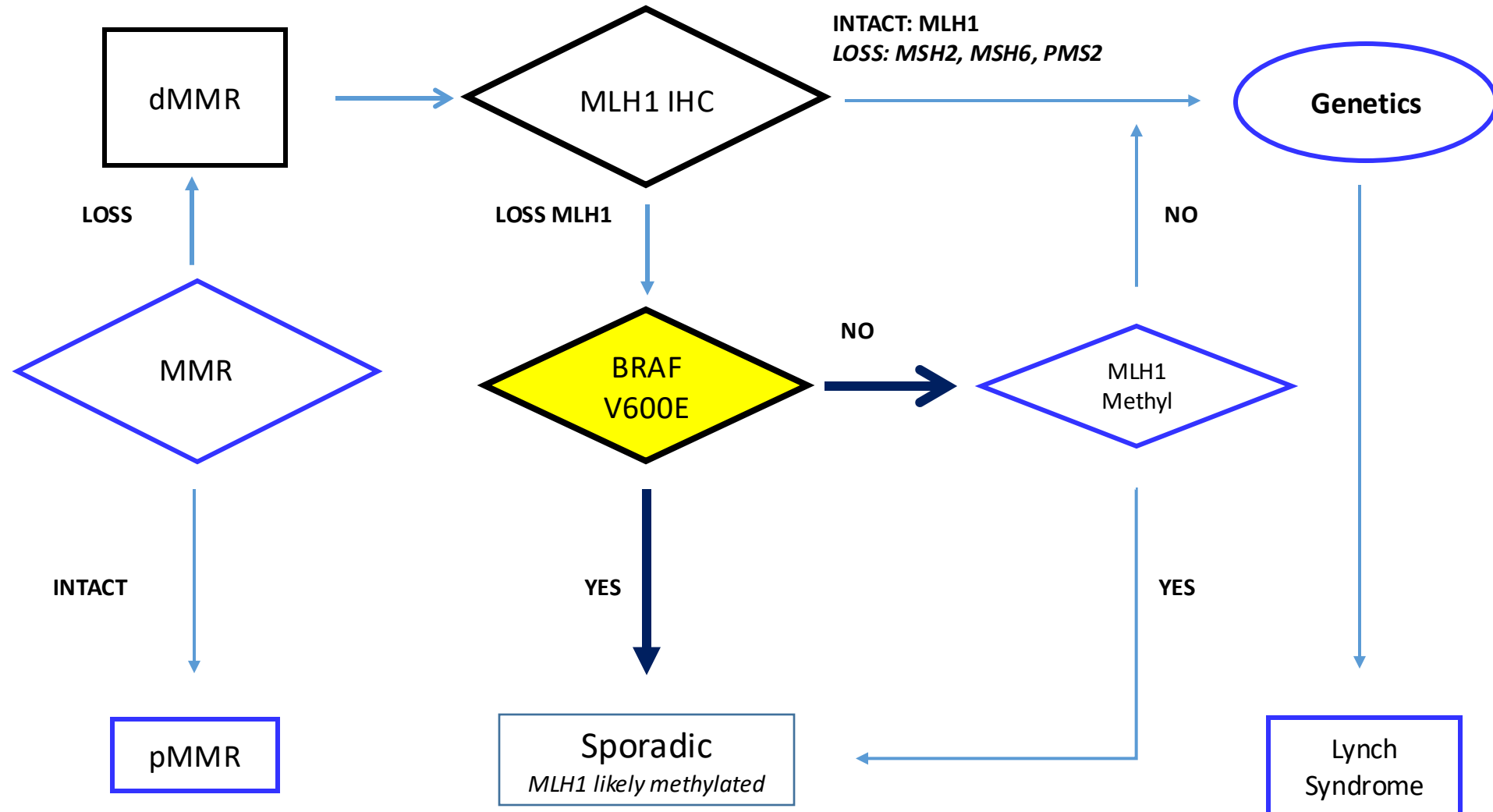


Normal

Tumor



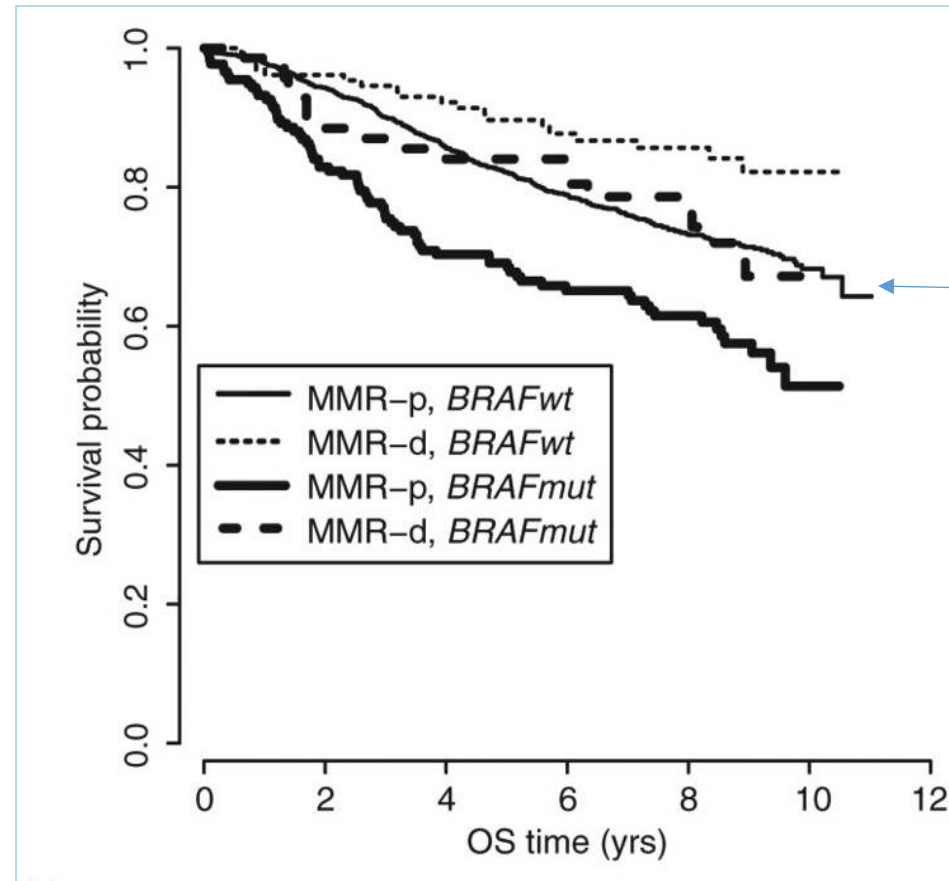
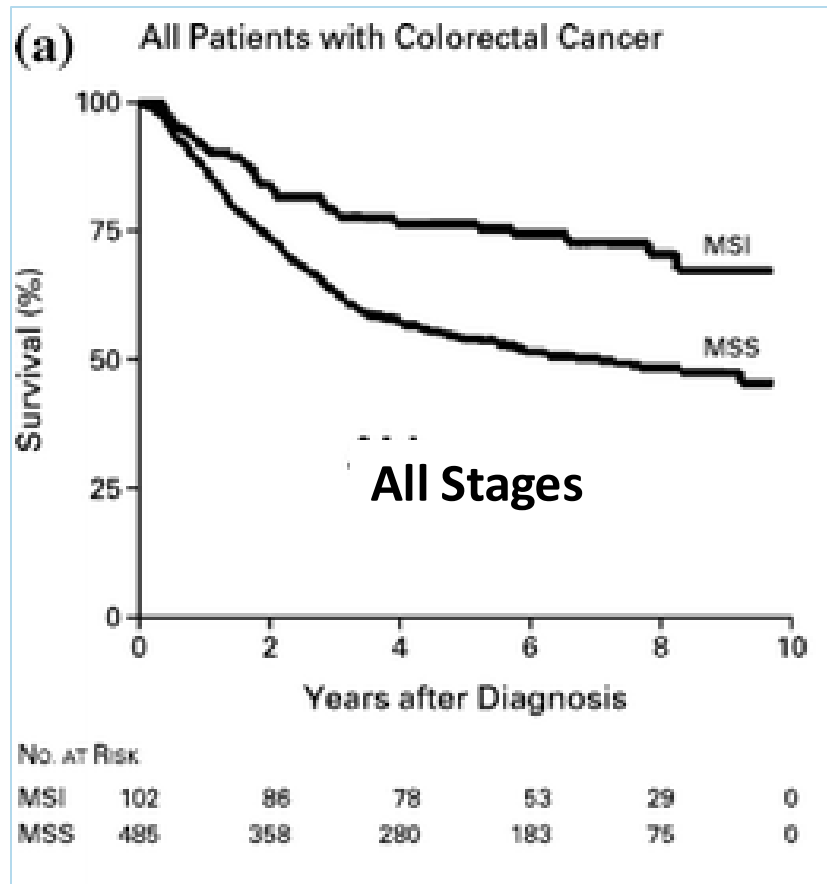
# Role for BRAF V600E testing to rule out LS in MLH1 deficient CRC



# pMMR and BRAF WT have intermediate prognosis

MSI has better prognosis

BRAF negatively affects prognosis

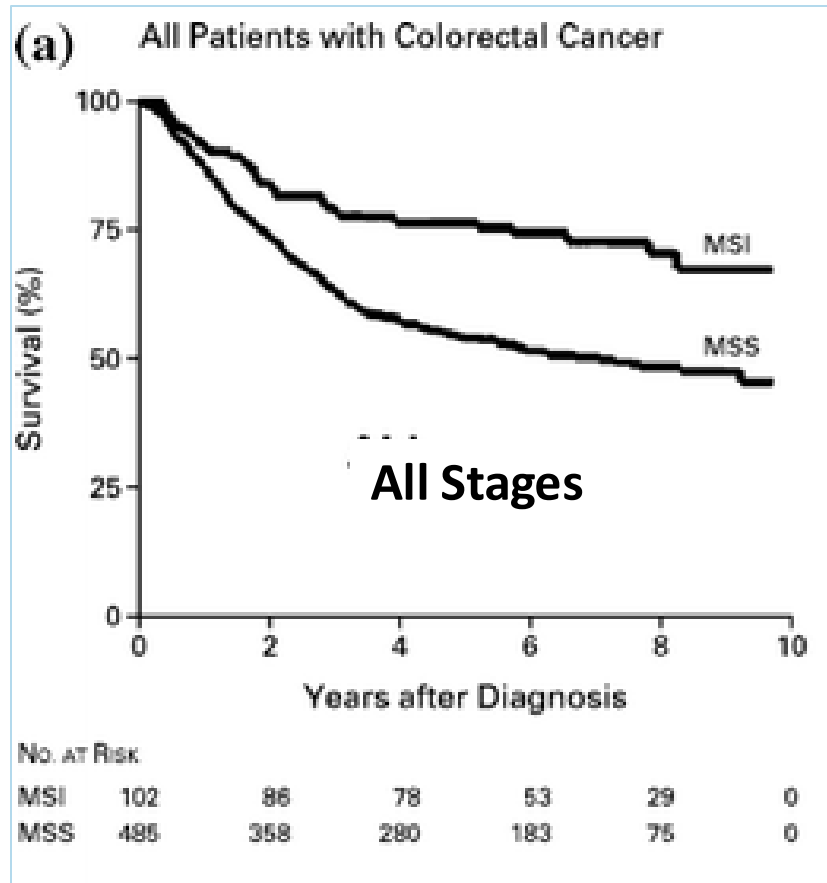


MMR	BRAF	Prognosis
-----	------	-----------

pMMR	WT	Intermediate
------	----	--------------

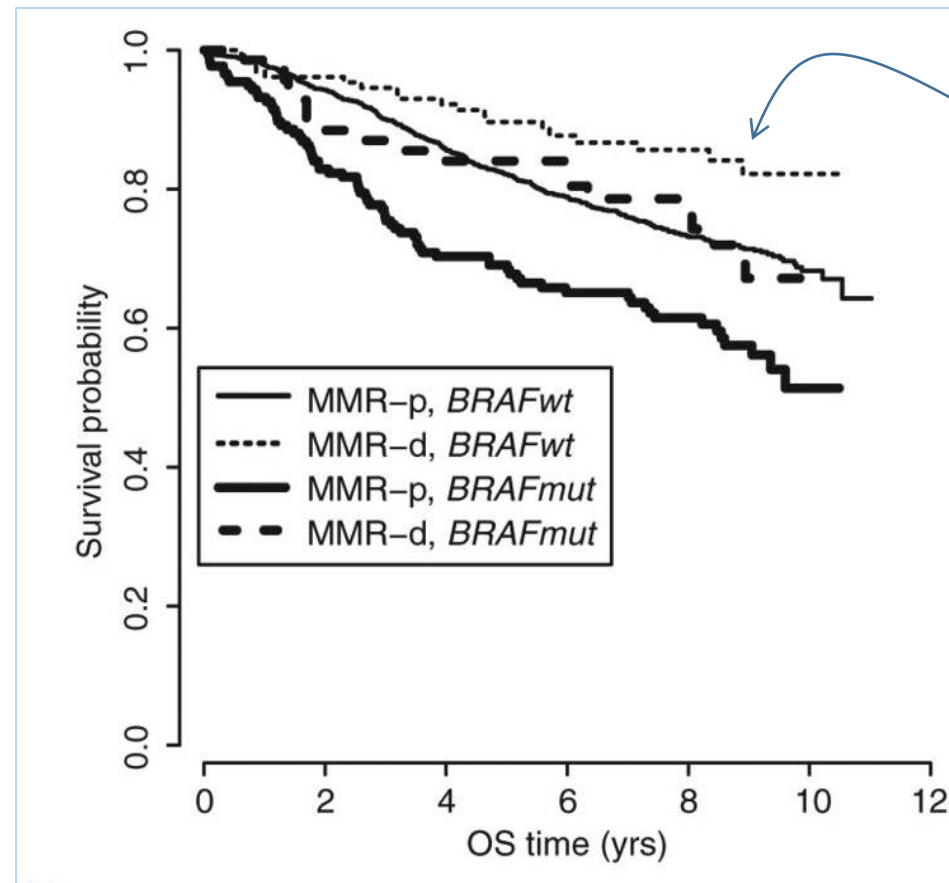
# dMMR has best prognosis

MSI has better prognosis



Ribic, NEJM, 349(3):247, 2003

BRAF negatively affects prognosis



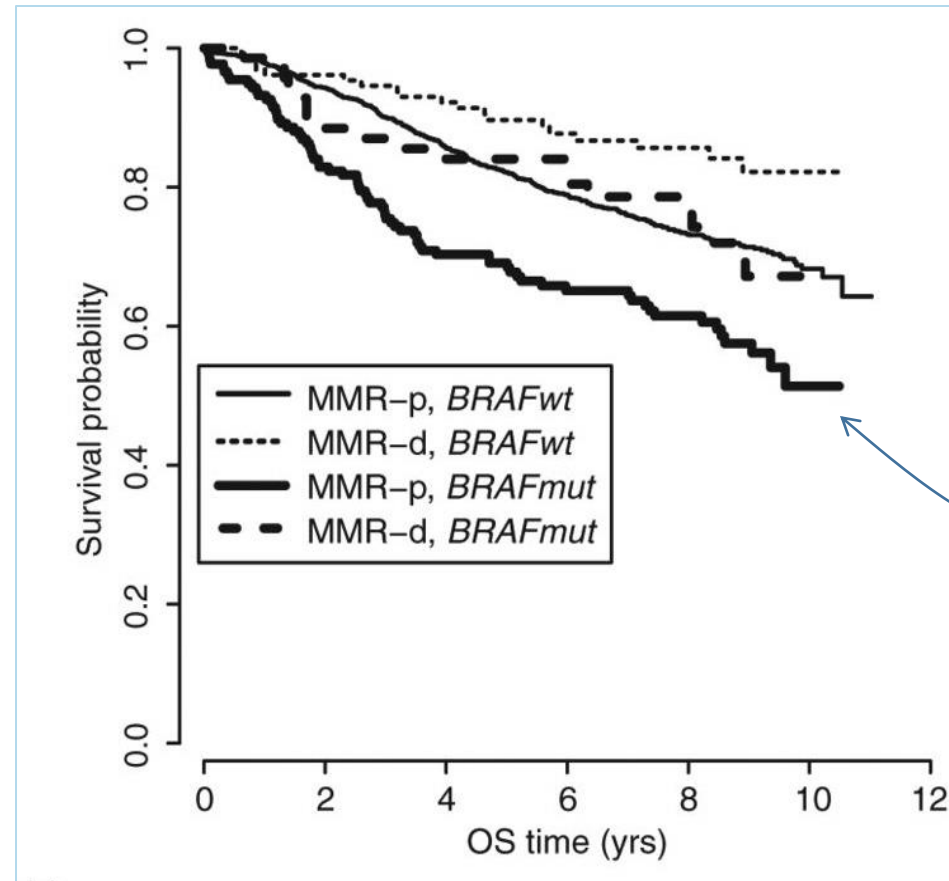
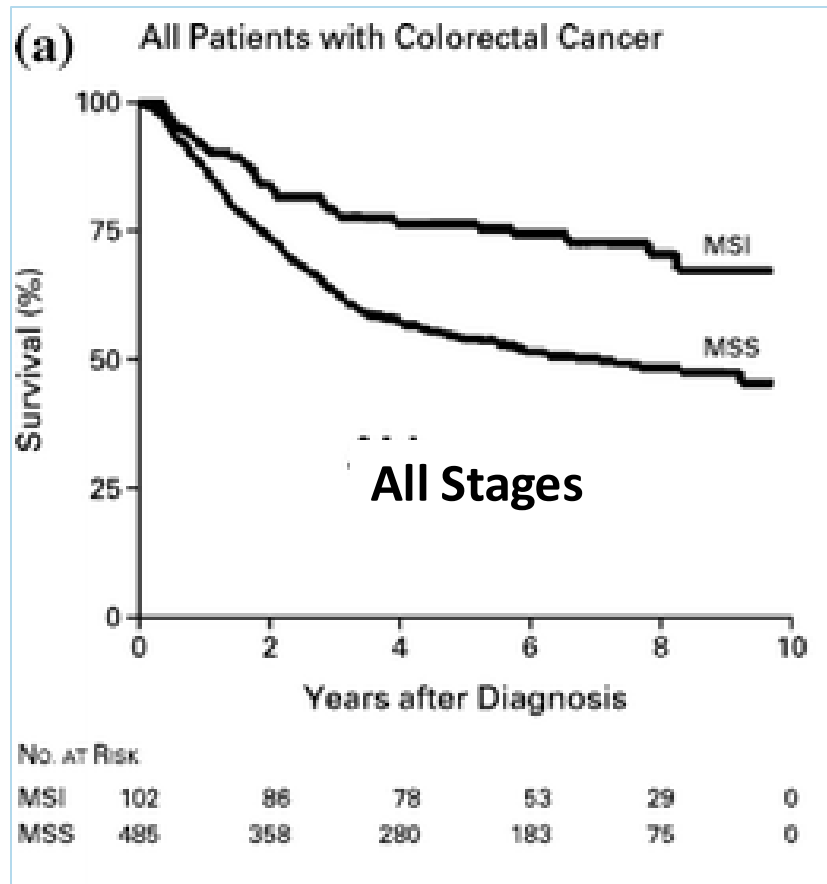
MMR	BRAF	Prognosis
dMMR	WT	Good

Gavin, P., CCR, V18(23), pp. 6531-6541, 2012

# BARF V600E has worst prognosis

MSI has better prognosis

BRAF negatively affects prognosis



MMR	BRAF	Prognosis
-----	------	-----------

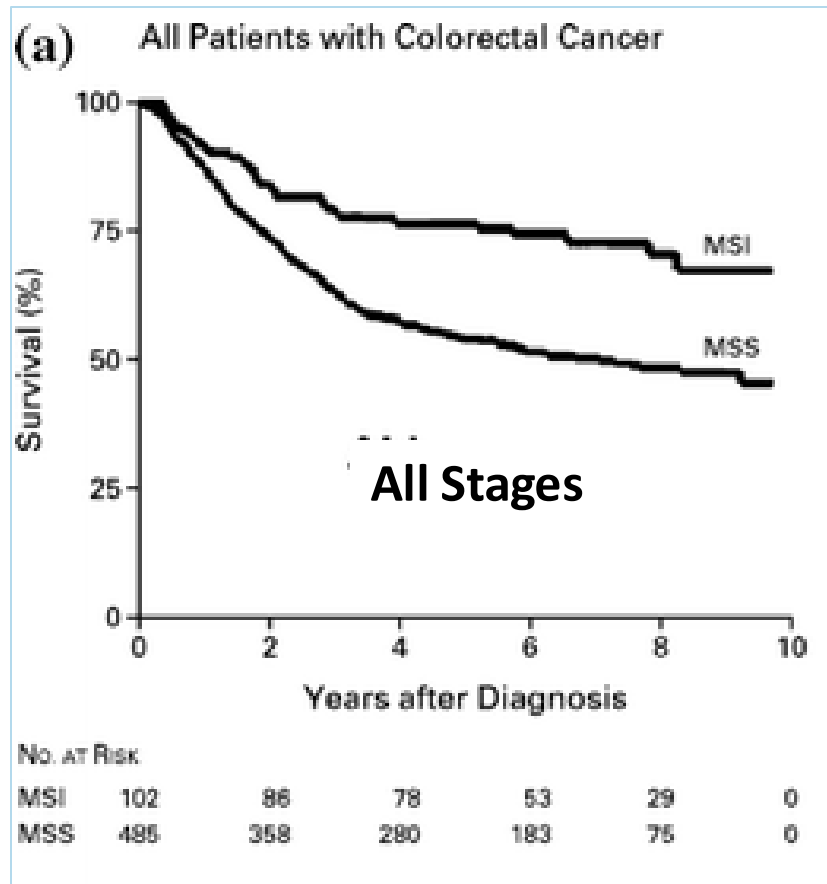
pMMR

V600E

Worse

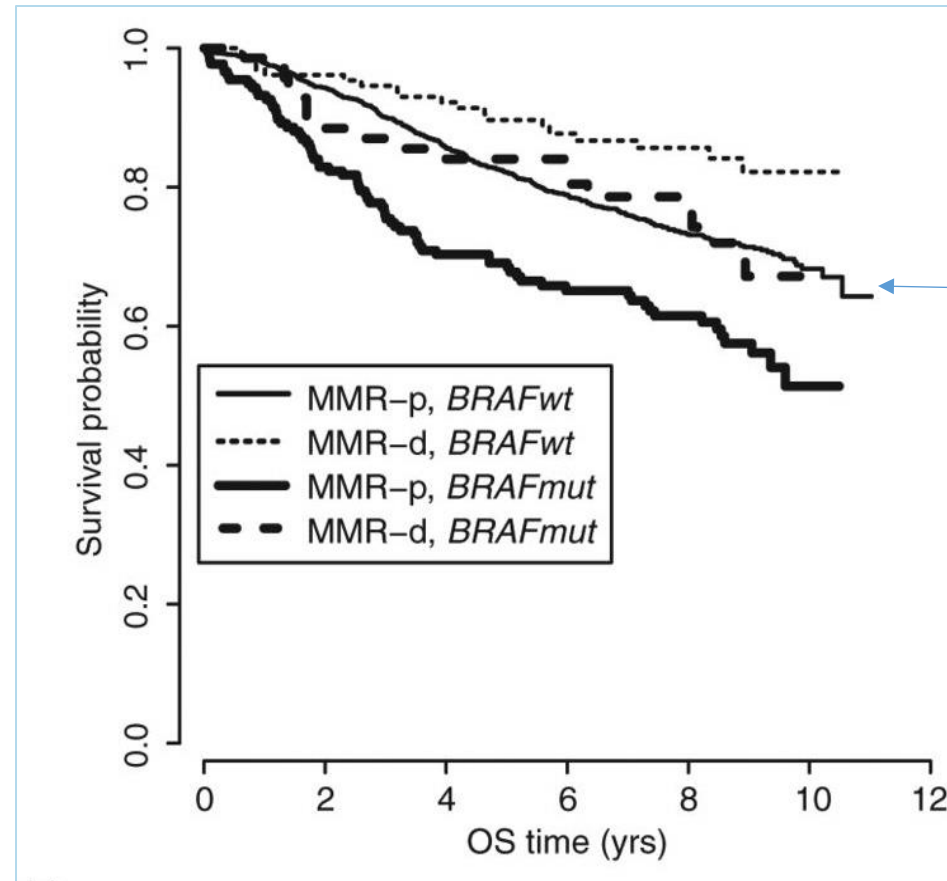
# dMMR/MSI modifies bad prognostic value of BRAF V600E

MSI has better prognosis



Ribic, NEJM, 349(3):247, 2003

BRAF negatively affects prognosis



MMR	BRAF	Prognosis
pMMR	WT	Intermediate
<b>dMMR</b>	<b>V600E</b>	<b>Intermediate</b>

Gavin, P., CCR, V18(23), pp. 6531-6541, 2012

# Back to our patient

## RECALL...

53 y/o male with clinical history of colon cancer

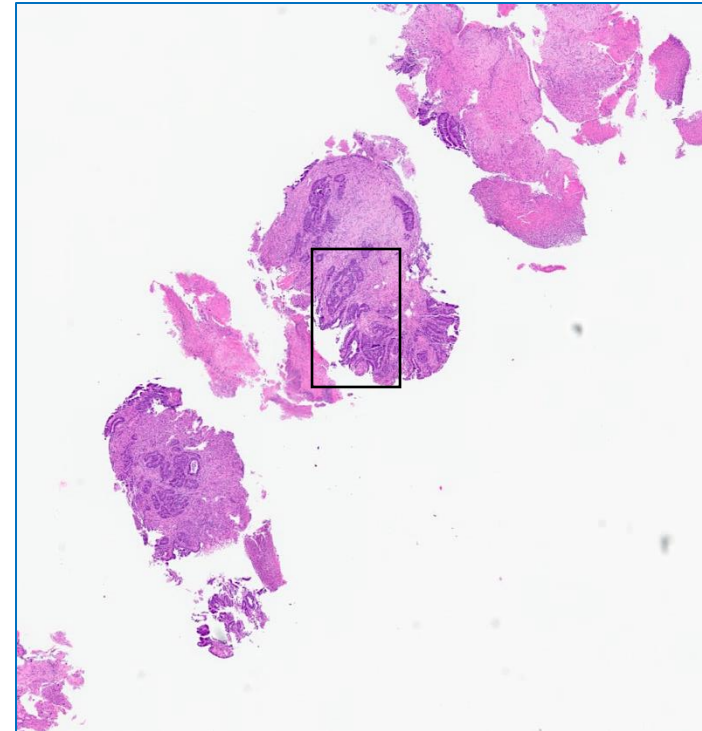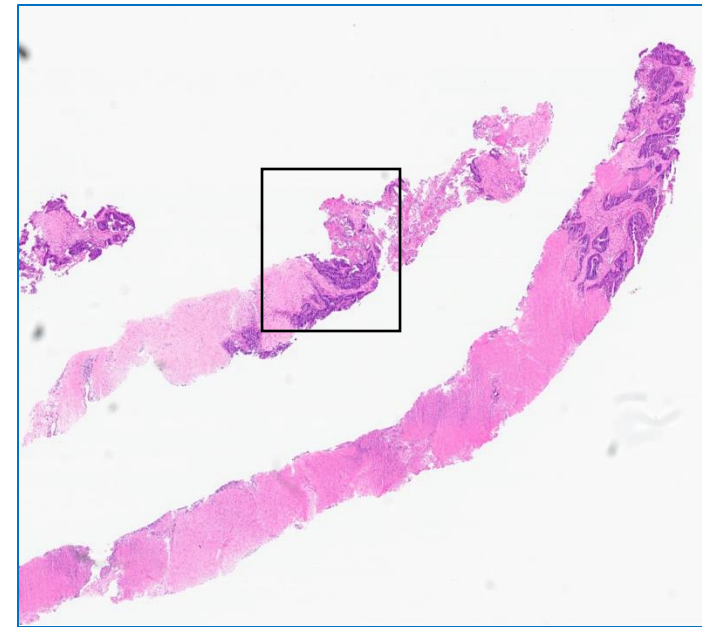
Referred for evaluation of recurrent/metastatic disease

Received two biopsies from recurrent disease

1. “Mass, cecal colon, biopsy” (VA hospital)
2. “Soft tissue, pelvic mass, biopsy” (UAB pathology)

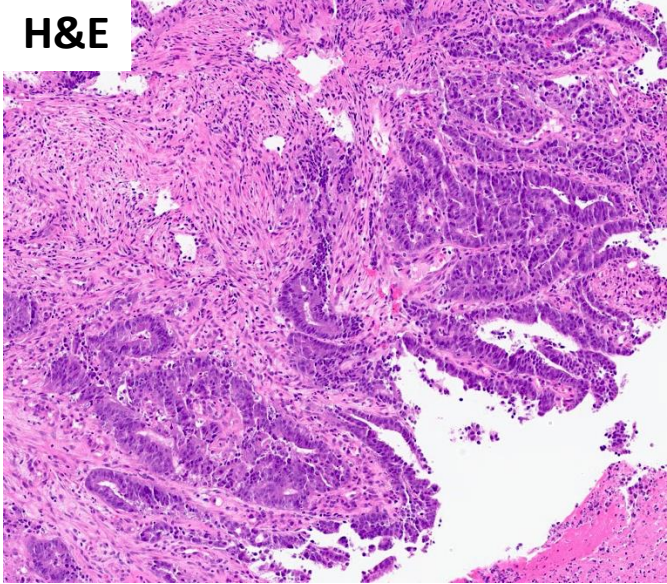
Reviewed by two pathologists

“Adenocarcinoma”

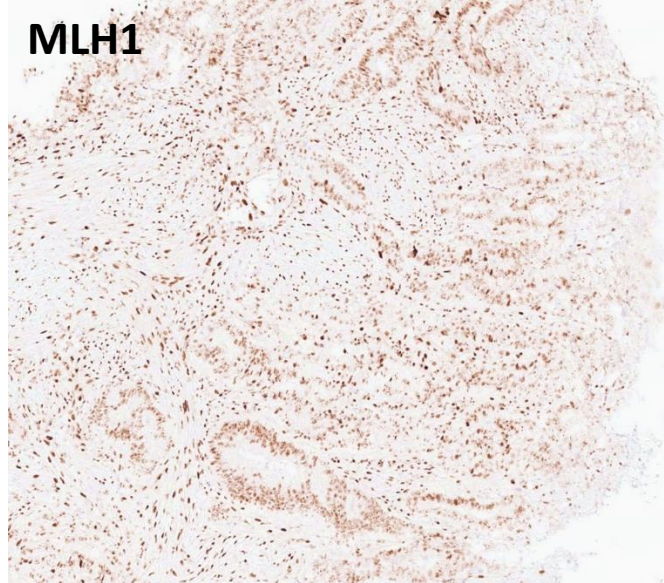


12/29/2023  
Cecal mass biopsy  
Adenocarcinoma

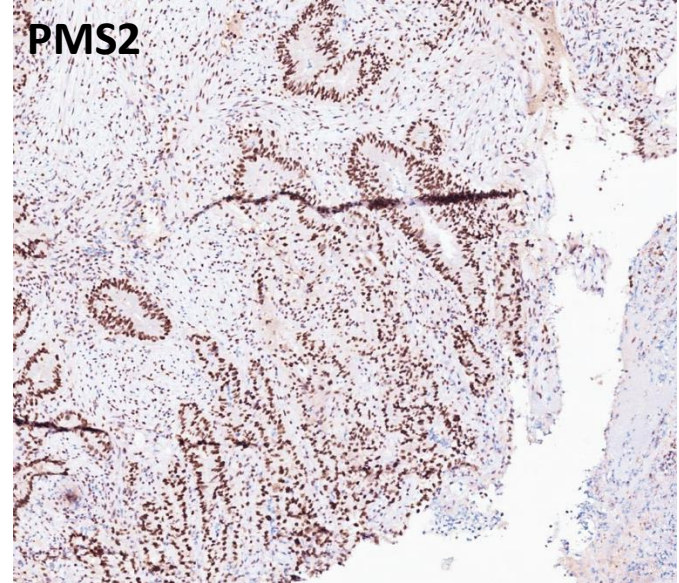
H&E



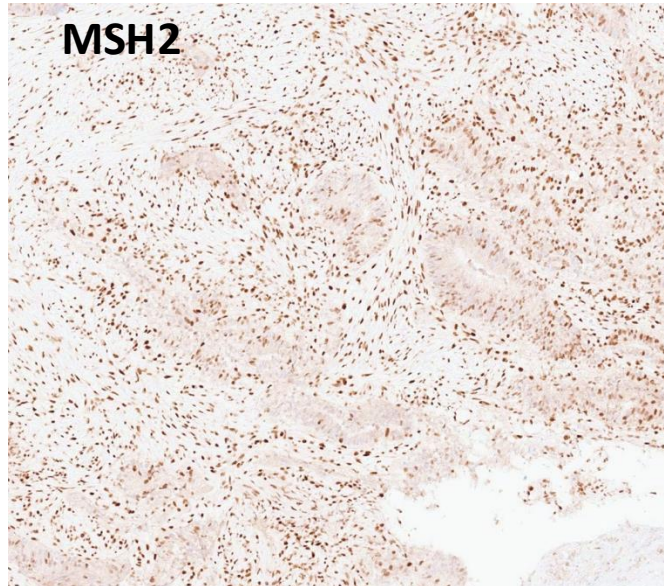
MLH1



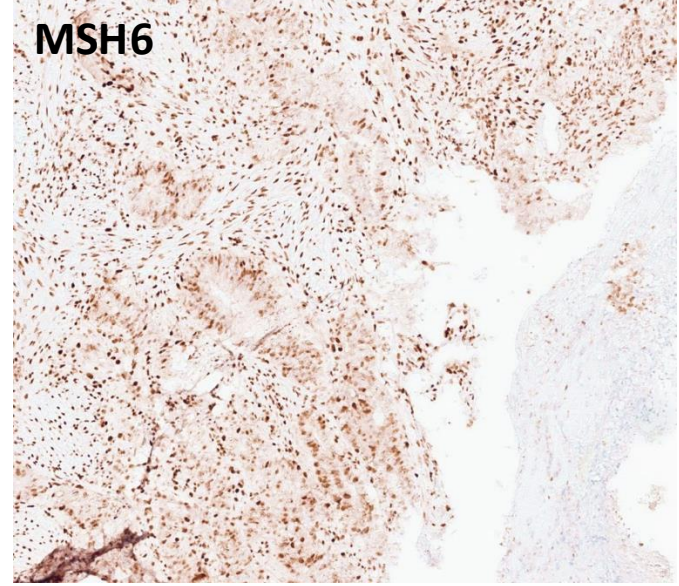
PMS2



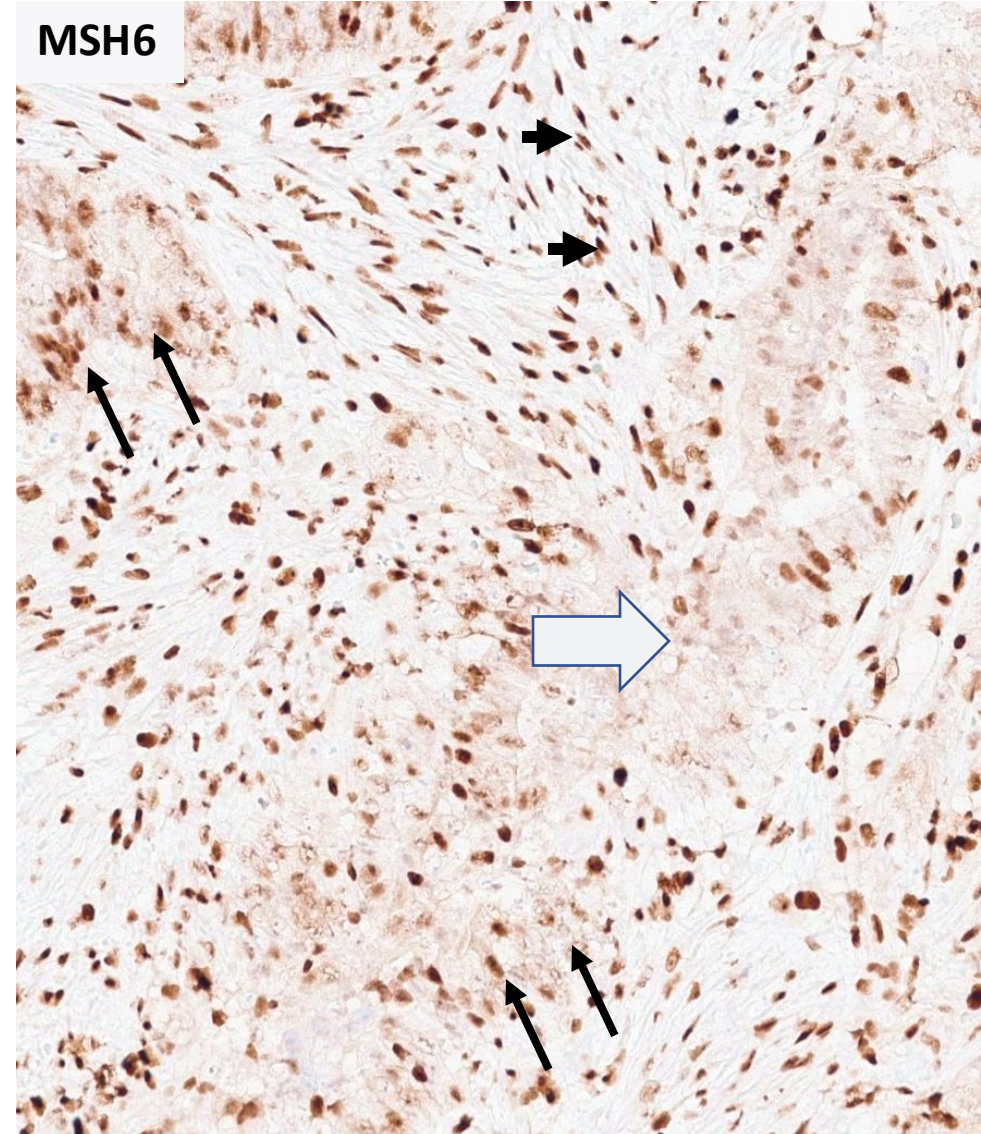
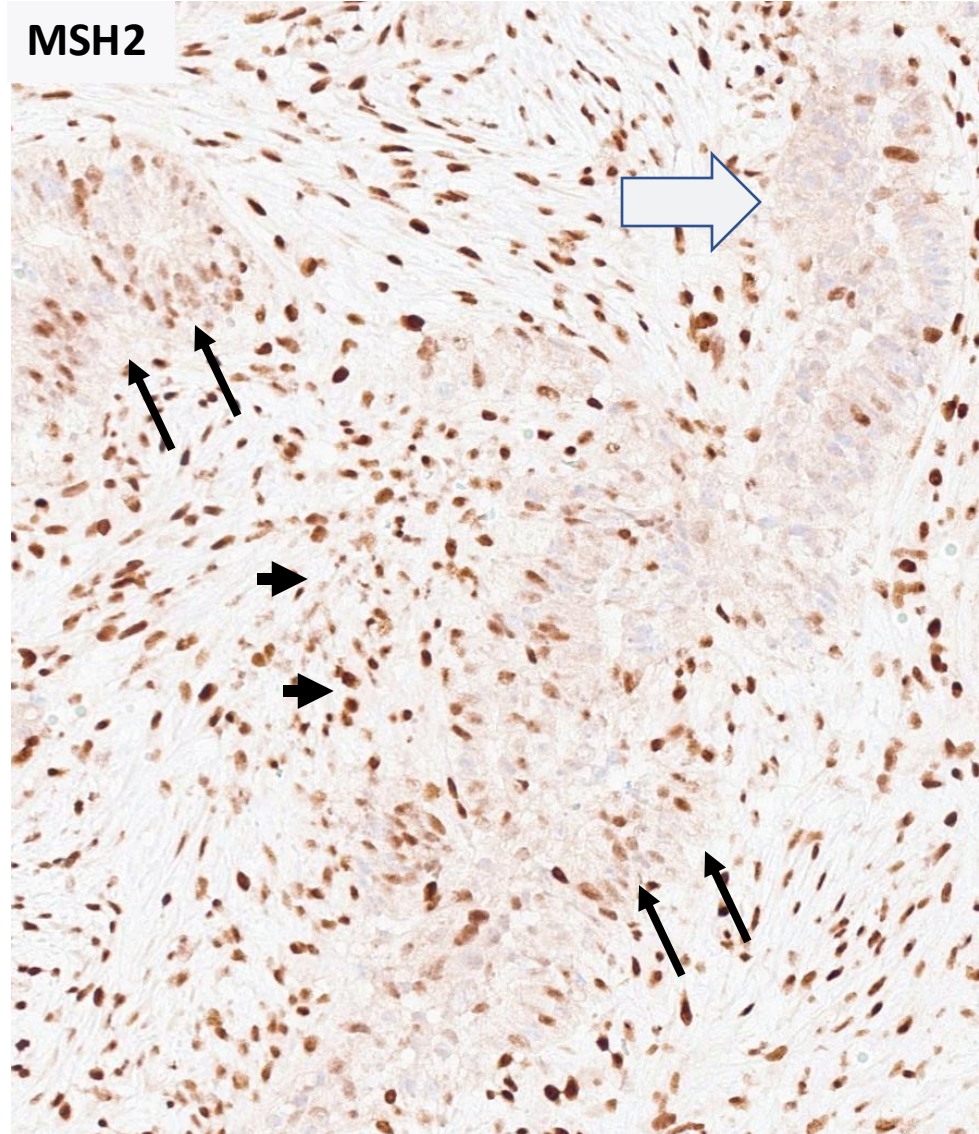
MSH2



MSH6



12/29/2023  
Cecal mass biopsy  
Adenocarcinoma

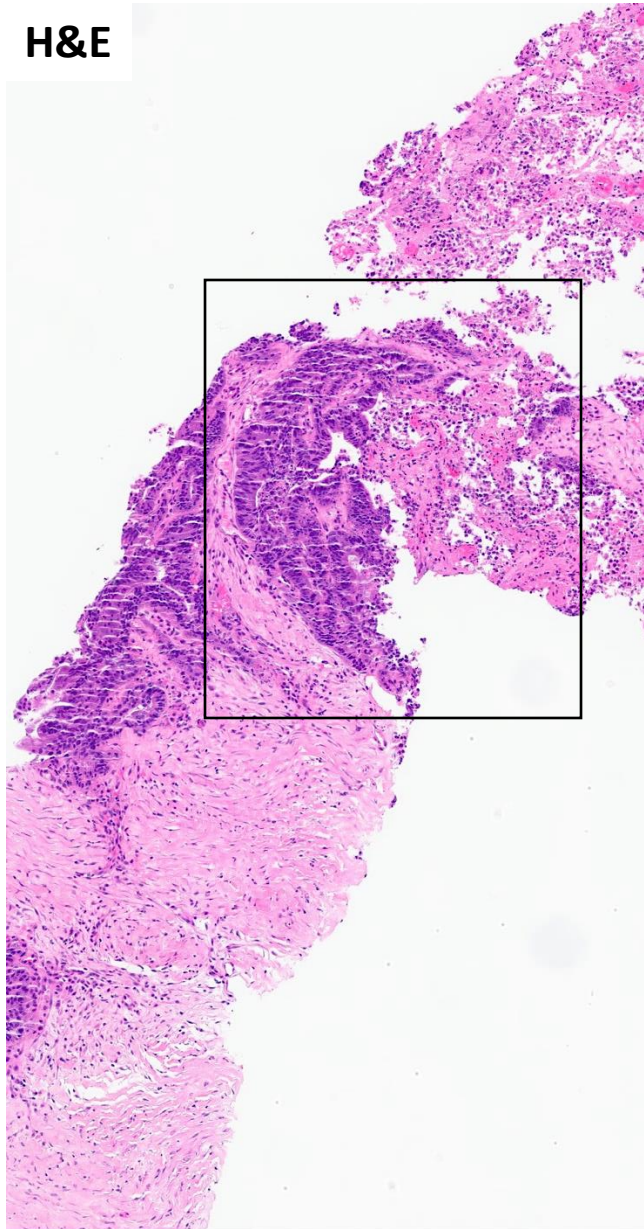


12/27/2023

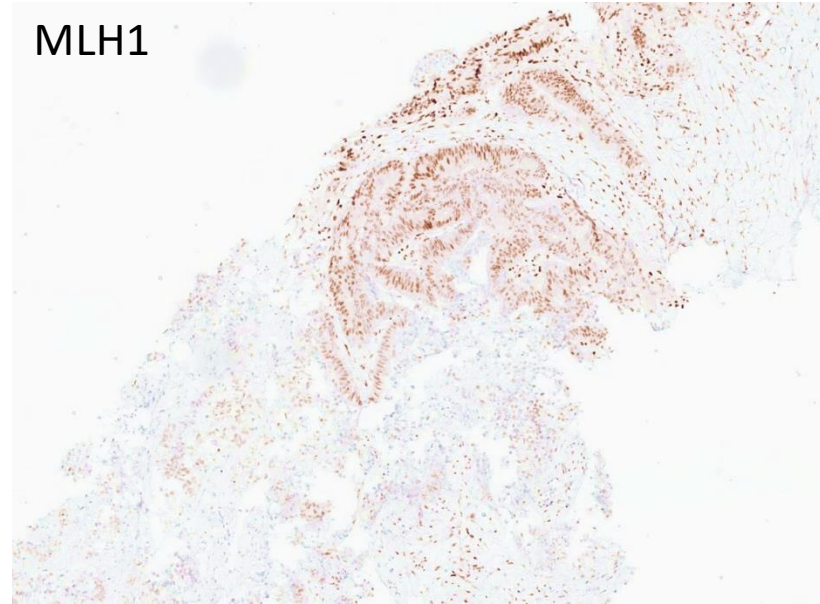
Soft tissue, pelvic mass, biopsy

Adenocarcinoma

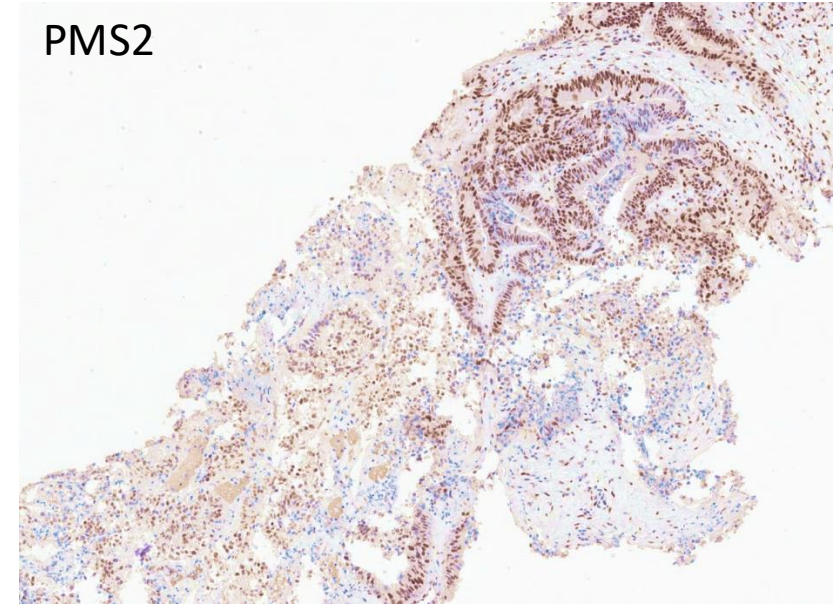
H&E



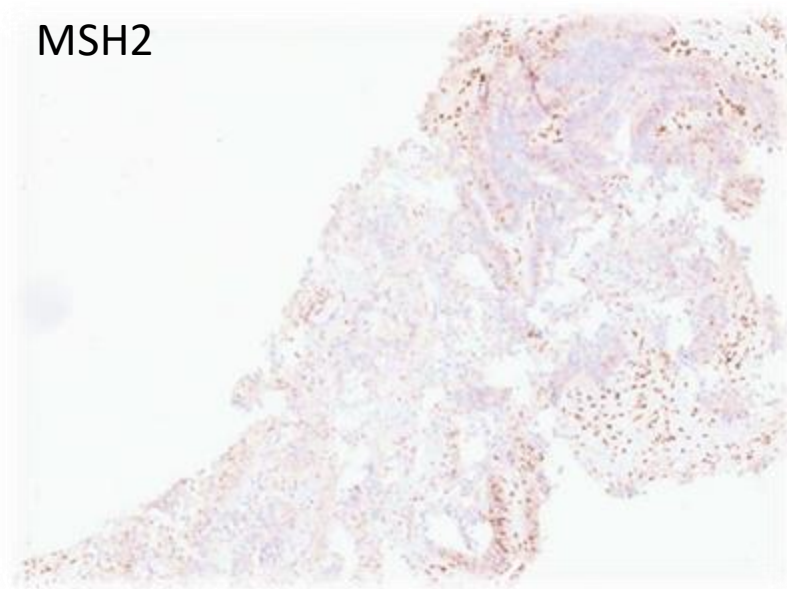
MLH1



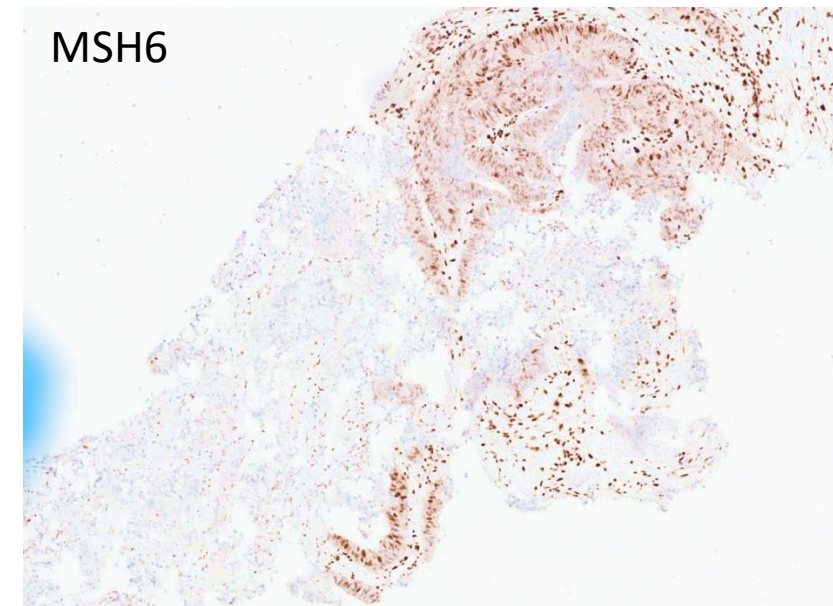
PMS2



MSH2



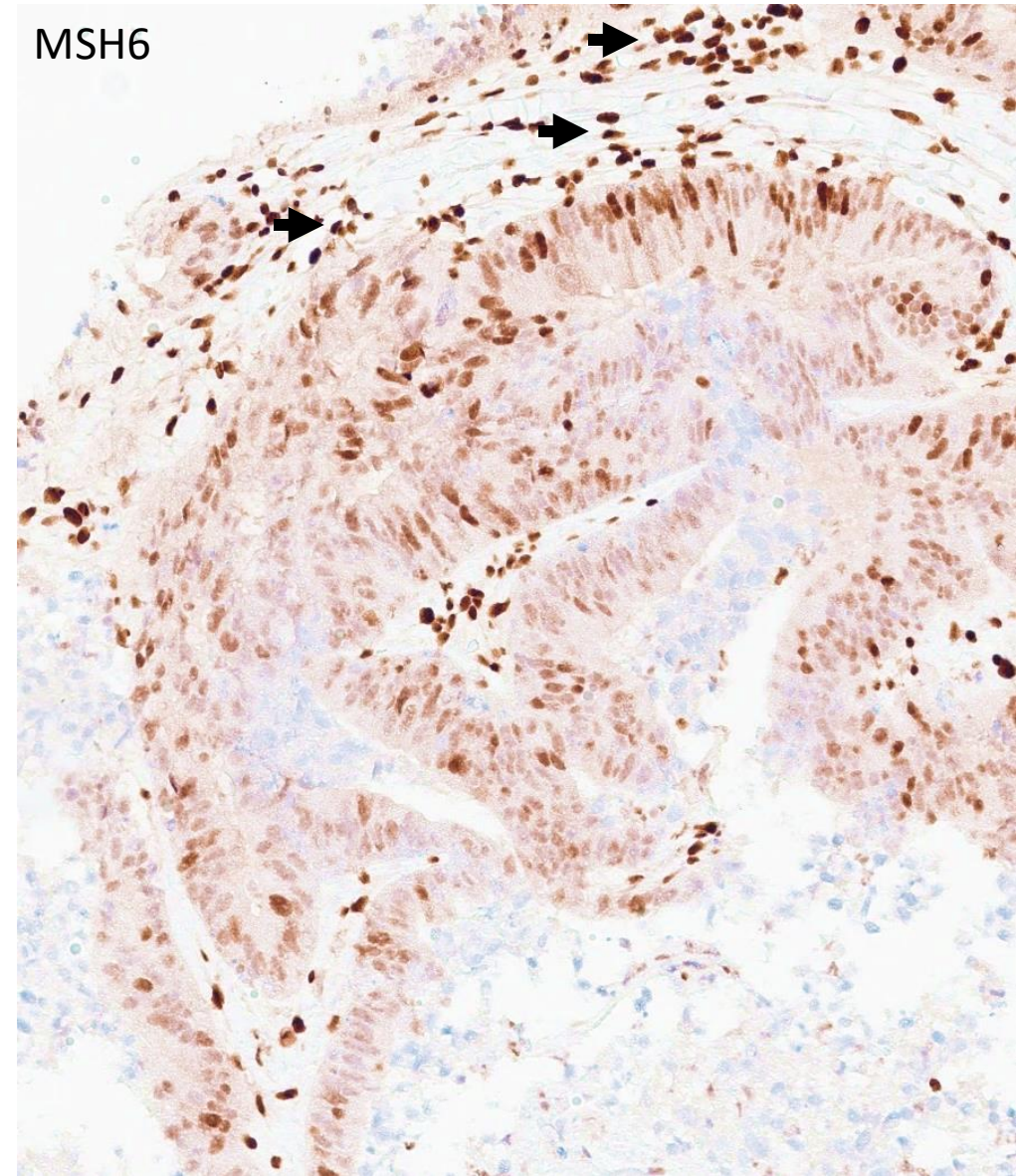
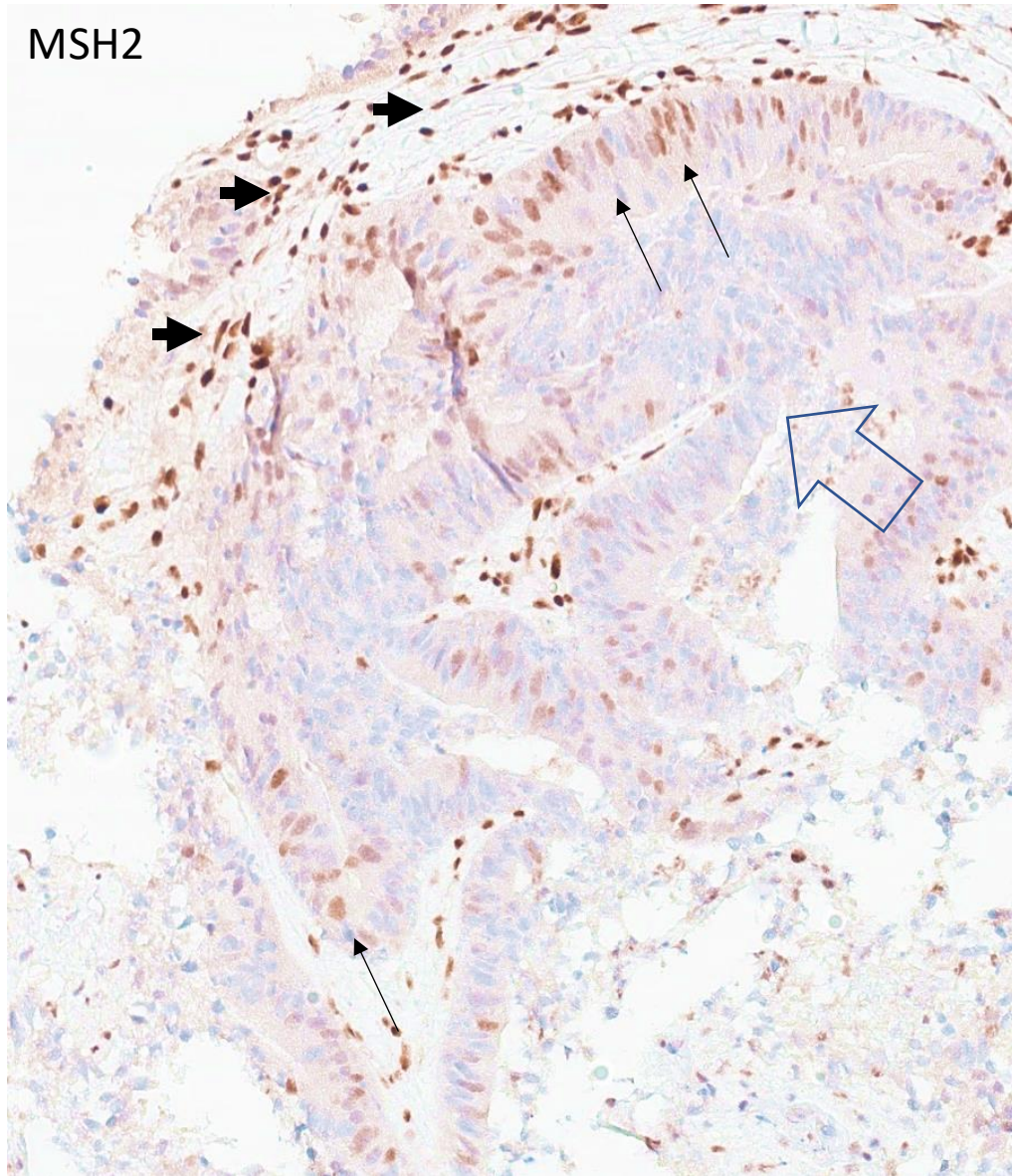
MSH6



12/27/2023

Soft tissue, pelvic mass, biopsy

Adenocarcinoma



# MMR IHC interpretation of both biopsies

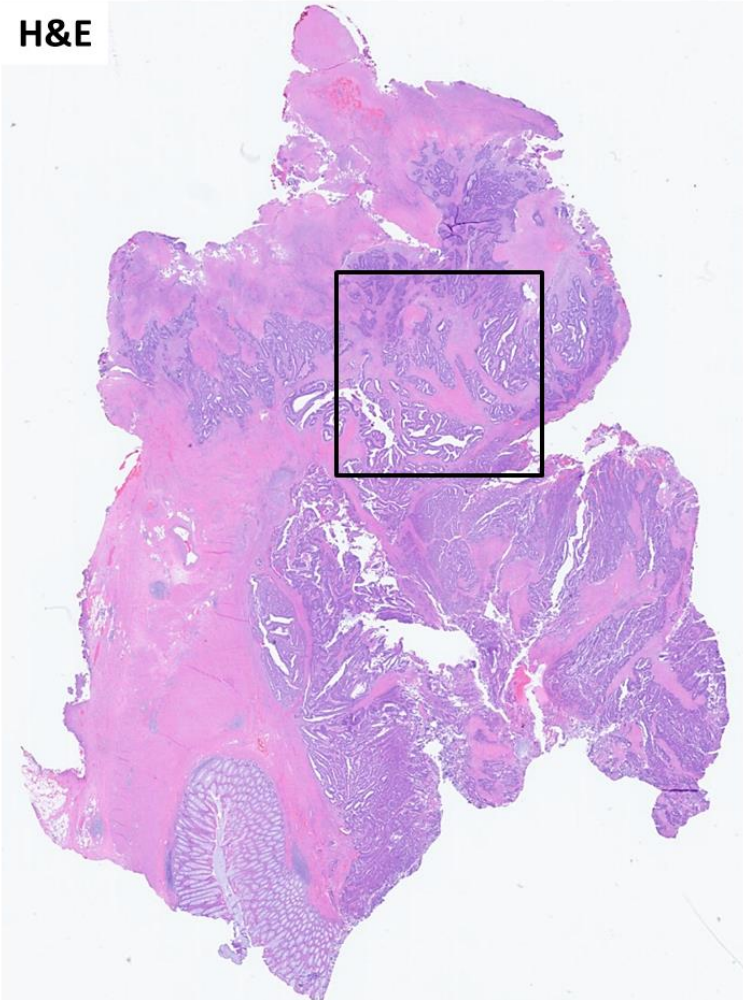
- MLH1 Expressed in tumor cells (Positive; retained)
- PMS2 Expressed in tumor cells (Positive; retained)
- MSH2 Expressed in tumor cells (Positive; retained)
- MSH6 Expressed in tumor cells (Positive; retained)

# Reviewed the pathology of the primary tumor (outside institution)

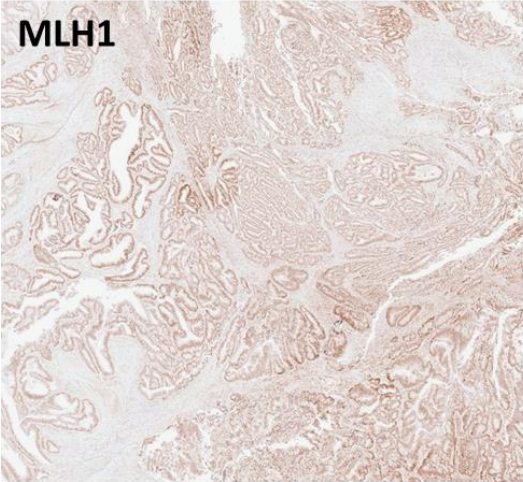
## Sigmoid colon and rectum:

Moderately to poorly differentiated adenocarcinoma (13.0 cm), extending to serosal margin. pT4a,N1a

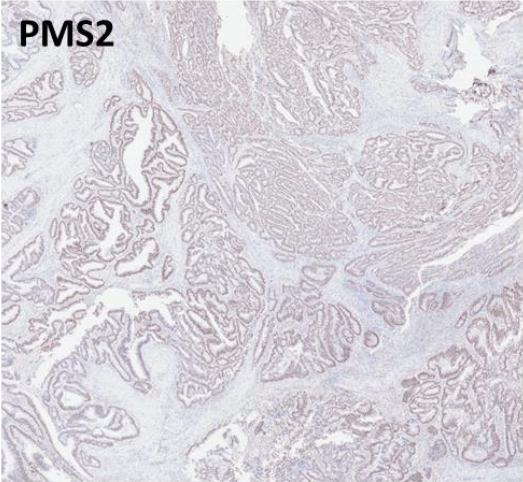
H&E



MLH1

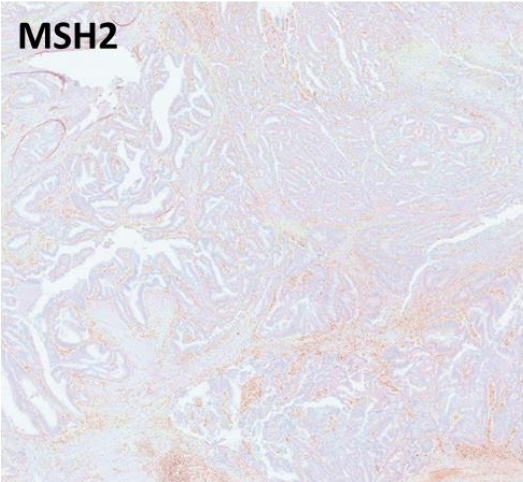


PMS2

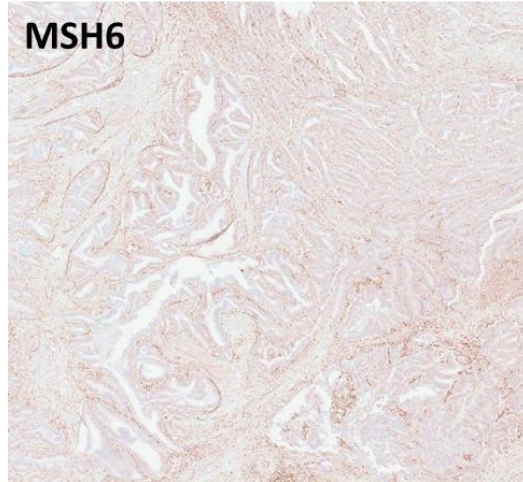


MLH1= positive nuclear  
PMS2= positive nuclear

MSH2

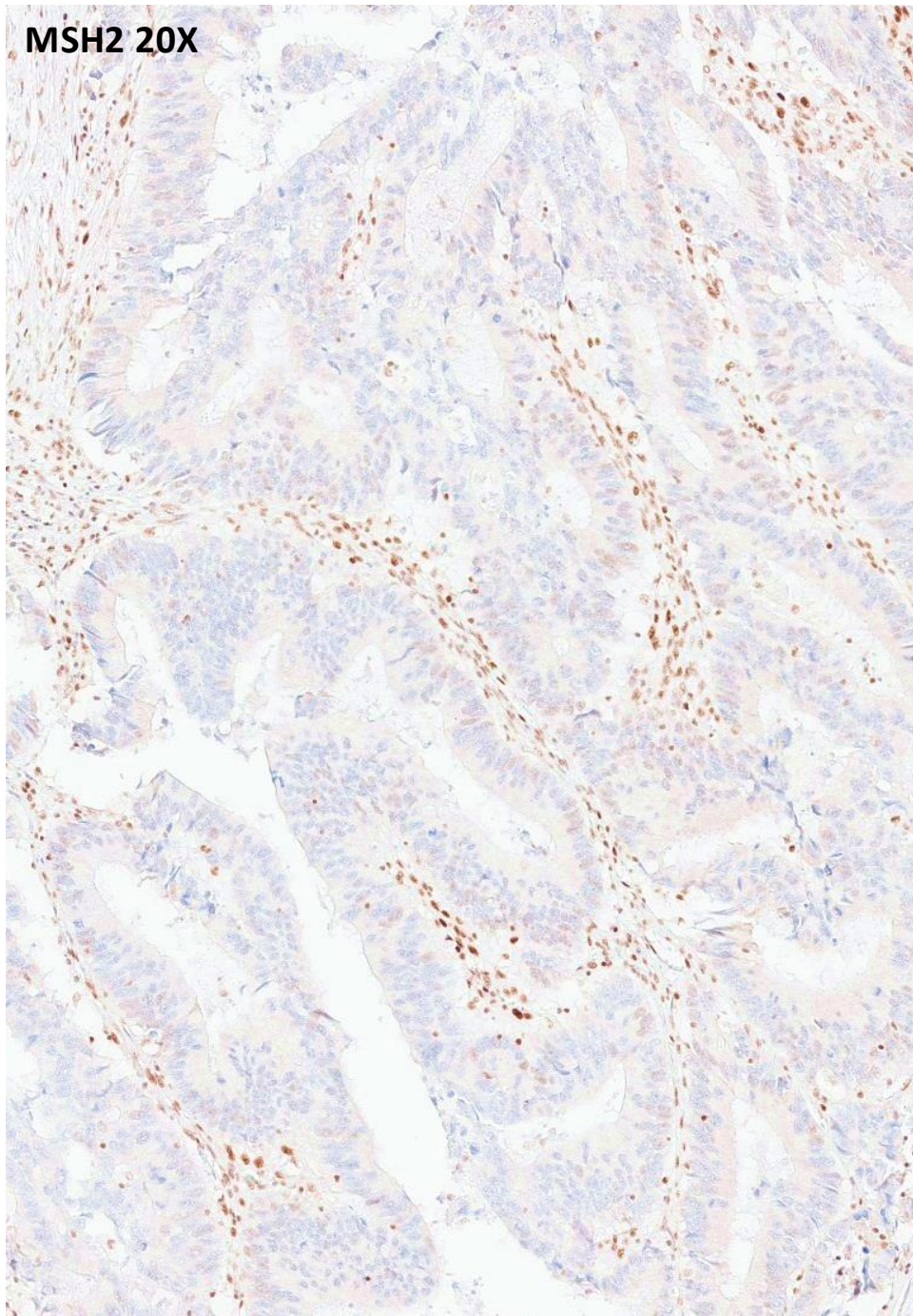


MSH6

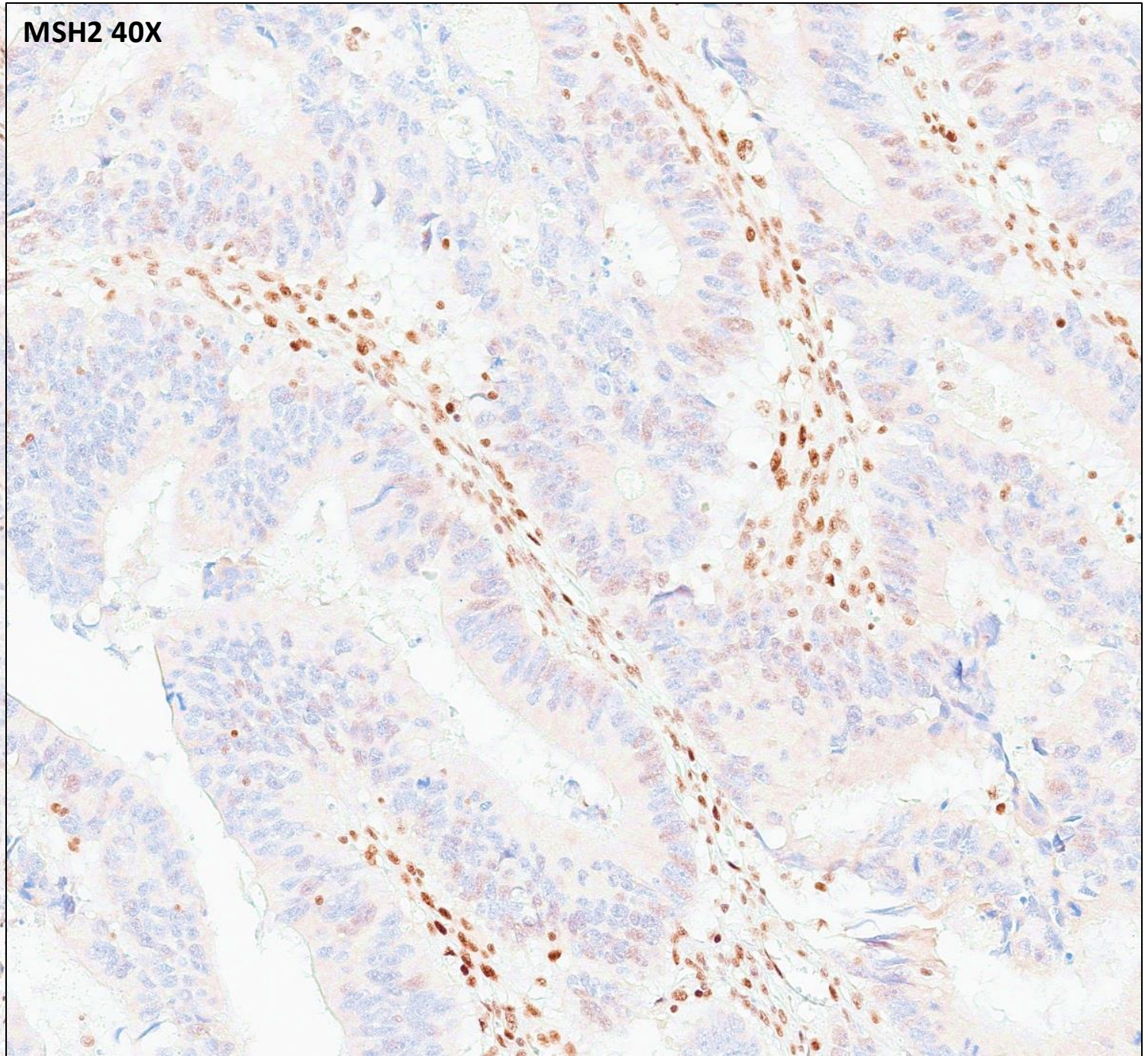


MSH2= loss of staining  
MSH6= patchy attenuated staining

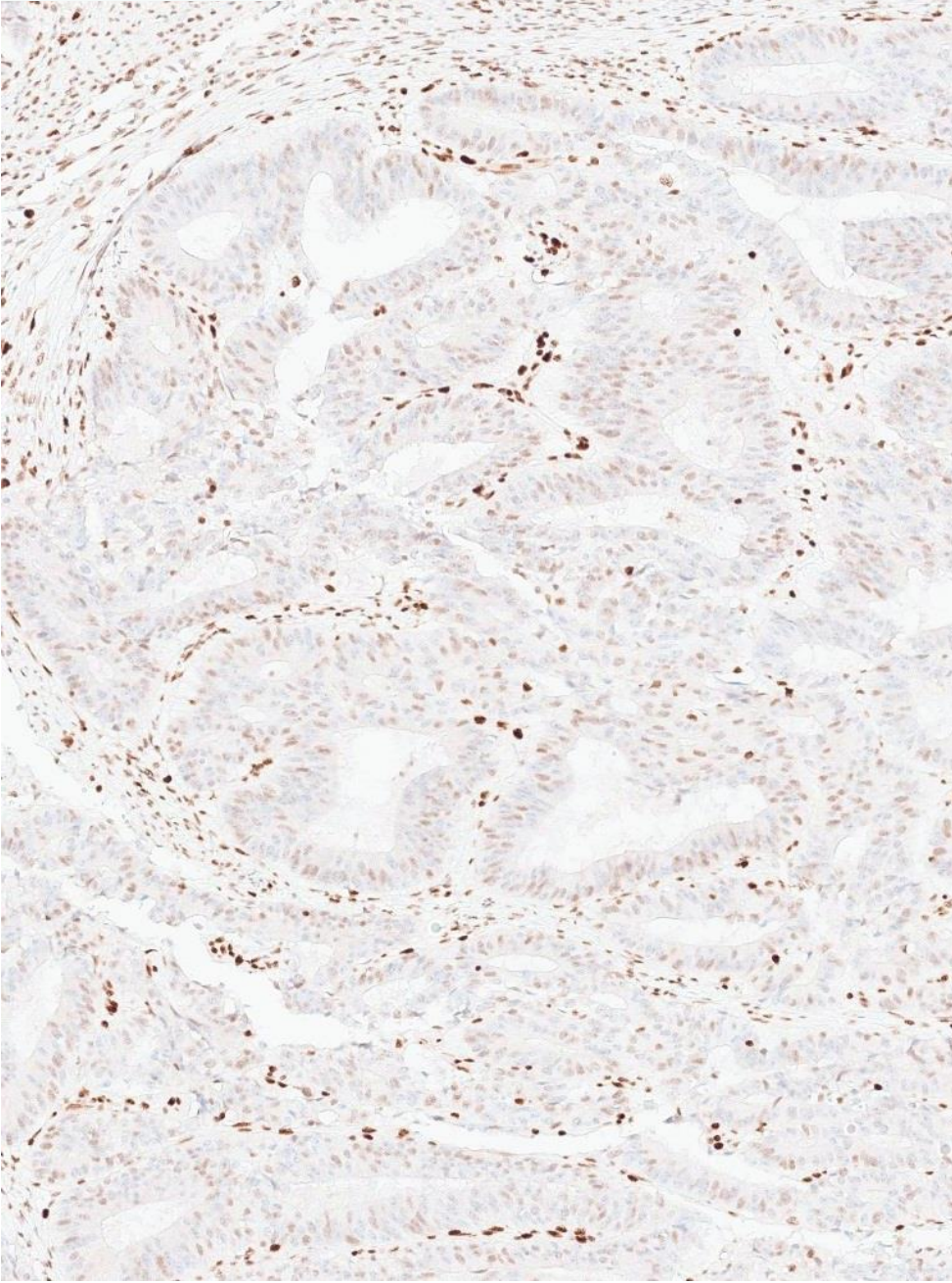
**MSH2 20X**



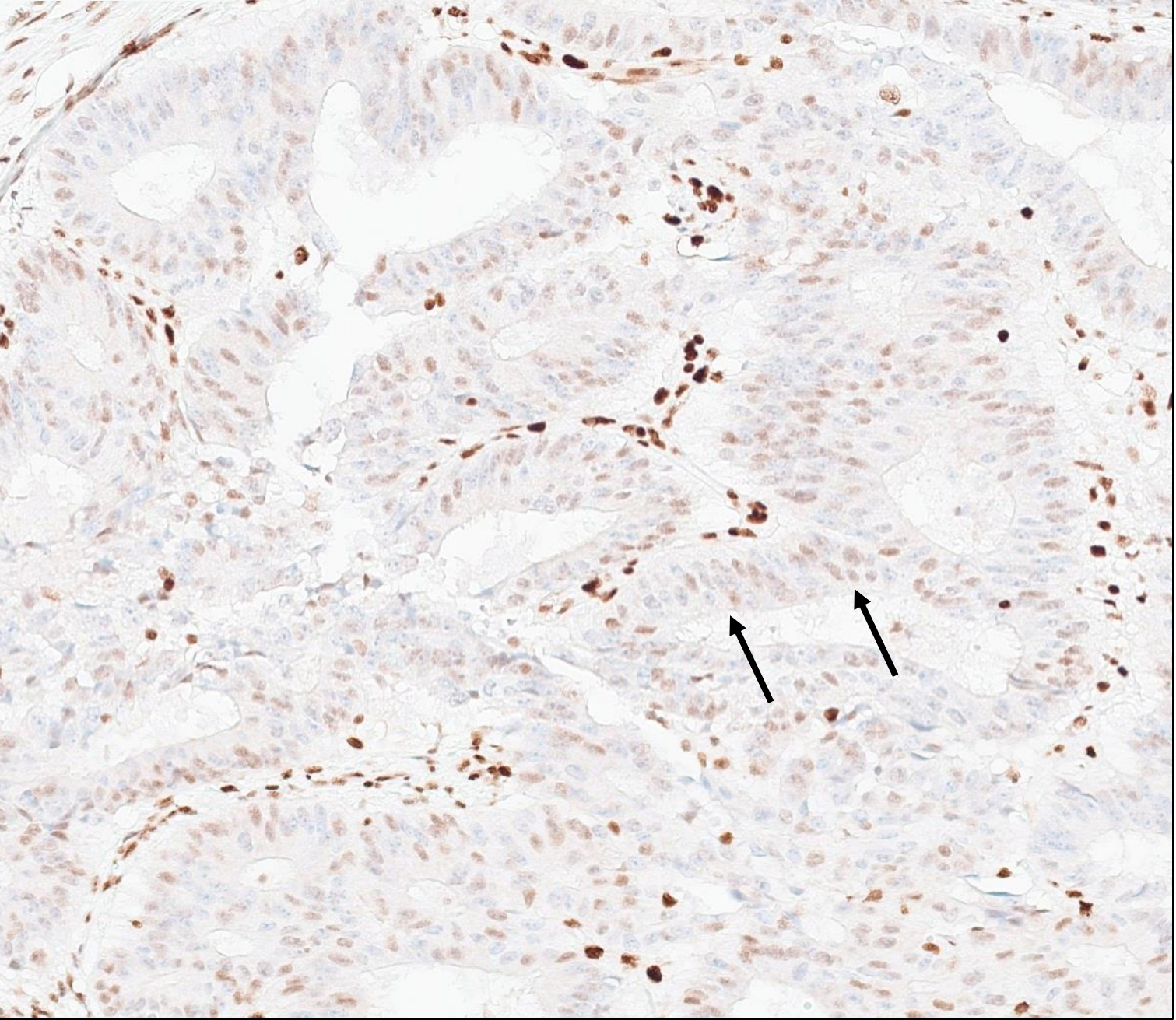
**MSH2 40X**



**MSH6 20X**



**MSH6 40X**

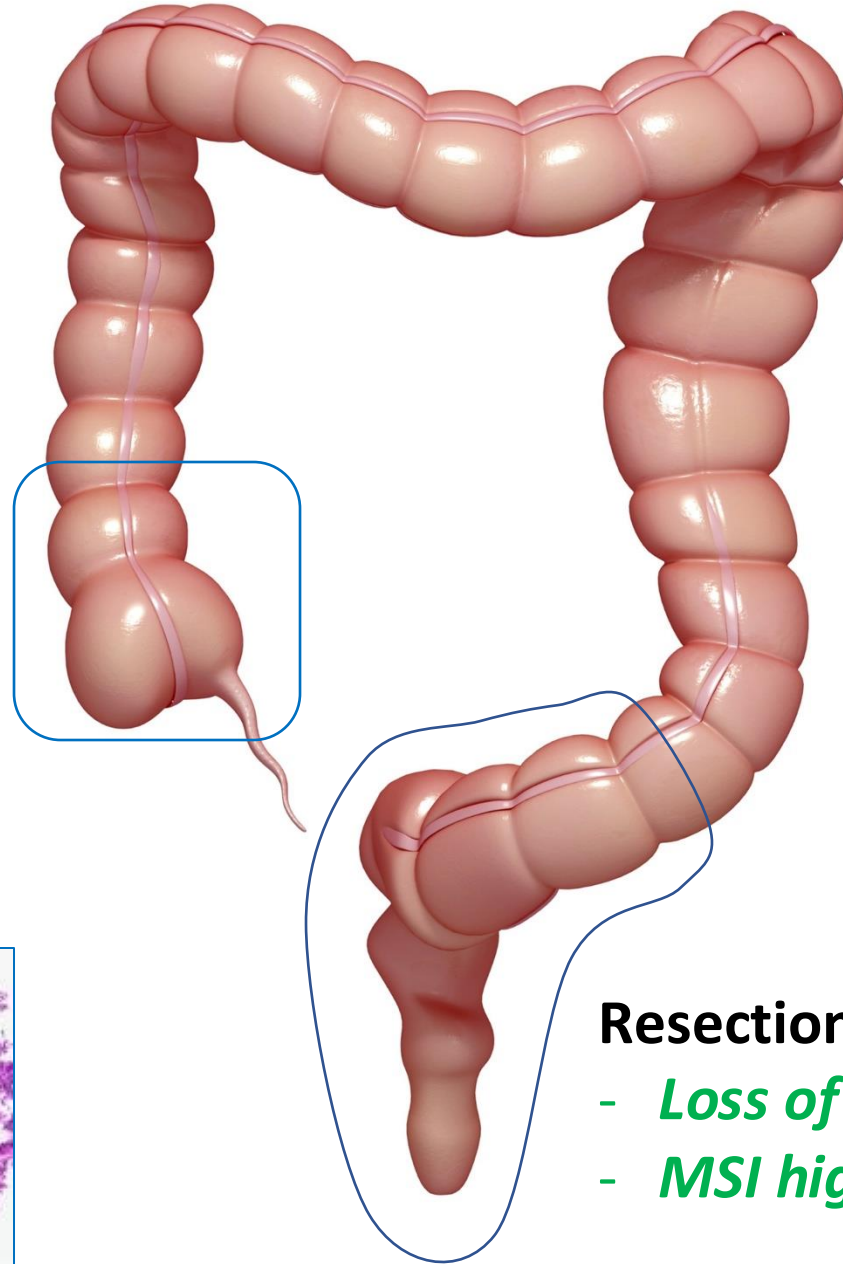
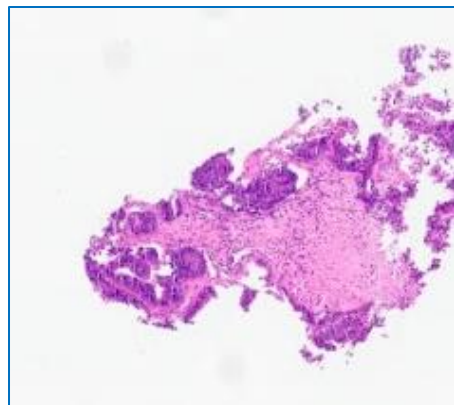


**Biopsy: Cecal Mass**

- *MMR intact*
- *MSI-High (5/7)*

**Biopsy: Pelvic Mass**

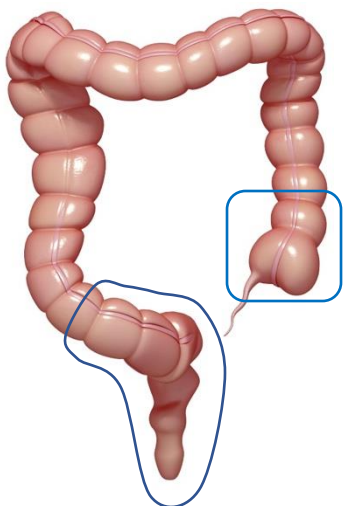
- *MMR intact*
- *MSI (6/7)*



**Resection: Sigmoid Colon, Rectum**

- *Loss of MSH2, MSH6*
- *MSI high (7/7)*

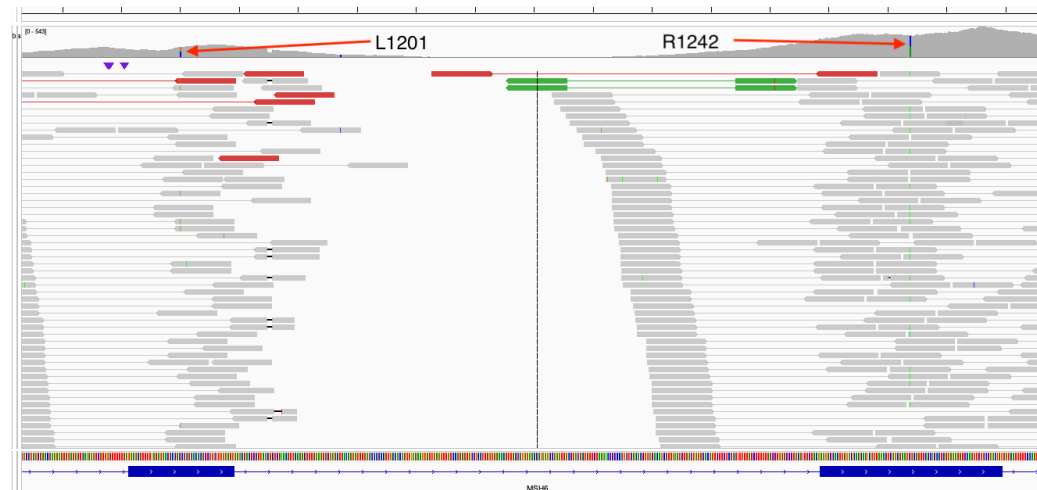
# NGS Results: Lynch Syndrome Diagnosis



Favor one tumor with dissemination versus synchronous tumors

*MSH6 p.L1201V (c.3601C>G)*

*MSH6 p.R1242S (c.3724C>A)*

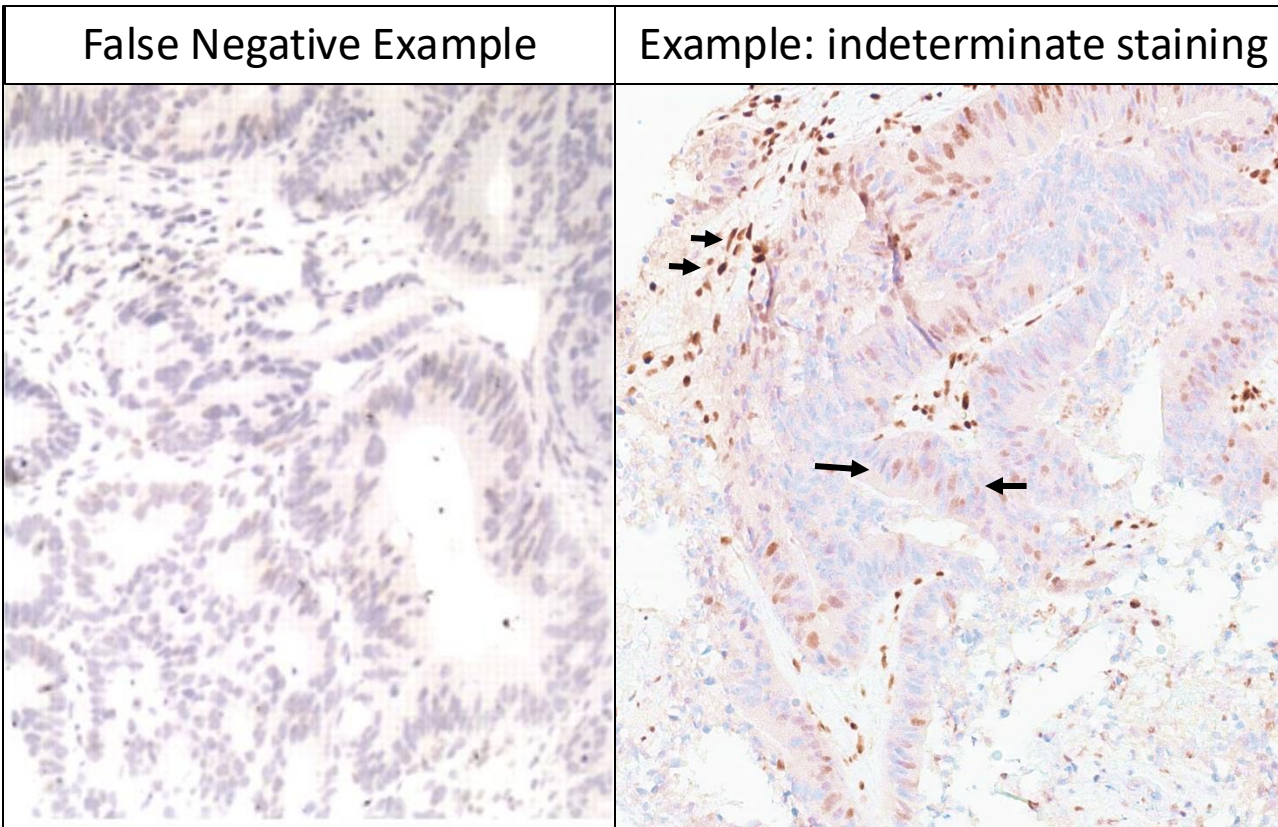


Resected Sigmoid Colon	Biopsy: Cecal Mass
Collection: 7/28/2023	Collection: 12/29/2023
MSI: Indeterminate	MSI: High
TMB: 36.9 Mut/Mb	TMB: 125.4 Muts/Mb
Pathogenic Mutations: <b>17 variants</b>	Pathogenic Mutations: <b>17 original + 96 new (113 total)</b>
<i>MSH6 p.L1201V (c.3601C&gt;G) VAF: 41.3%</i>	<i>MSH6 p.L1201V (c.3601C&gt;G) VAF: 51%</i>
<i>MSH6 p.R1242S (c.3724C&gt;A) VAF: 46.5%</i>	<i>MSH6 p.R1242S (c.3724C&gt;A) VAF: 57%</i>

Family	Gene	Variant
6	<i>HNF1A</i>	c.695T>C (p.L232P)
<b>7</b>	<b><i>MSH6</i></b>	<b>p.L1201V (c.3601C&gt;G) p.R1242S (c.3724C&gt;A)</b>
8	<i>BRCA1</i>	5260T>G (p.V1714G)
9	<i>SDHD</i>	c.412G>A (p.G138R)
10	<i>MSH6</i>	c.3040del3 (p.K1014del)
11	<i>PMS2</i>	c.137G>T(p.Ser46Ile)
12	<i>BRCA1</i>	c.4484G>A (p.Arg1495Lys)
13	<i>BRCA1</i>	c.4484G>A (p.Arg1495Lys)

# Challenge with Discordant Results- *was there an error?*

1. *Preanalytical error*
2. *Interpretation error*



neoplastic glands and stromal cells:  
**BOTH** negative

neoplastic glands and stromal cells:  
**patchy, attenuated staining**

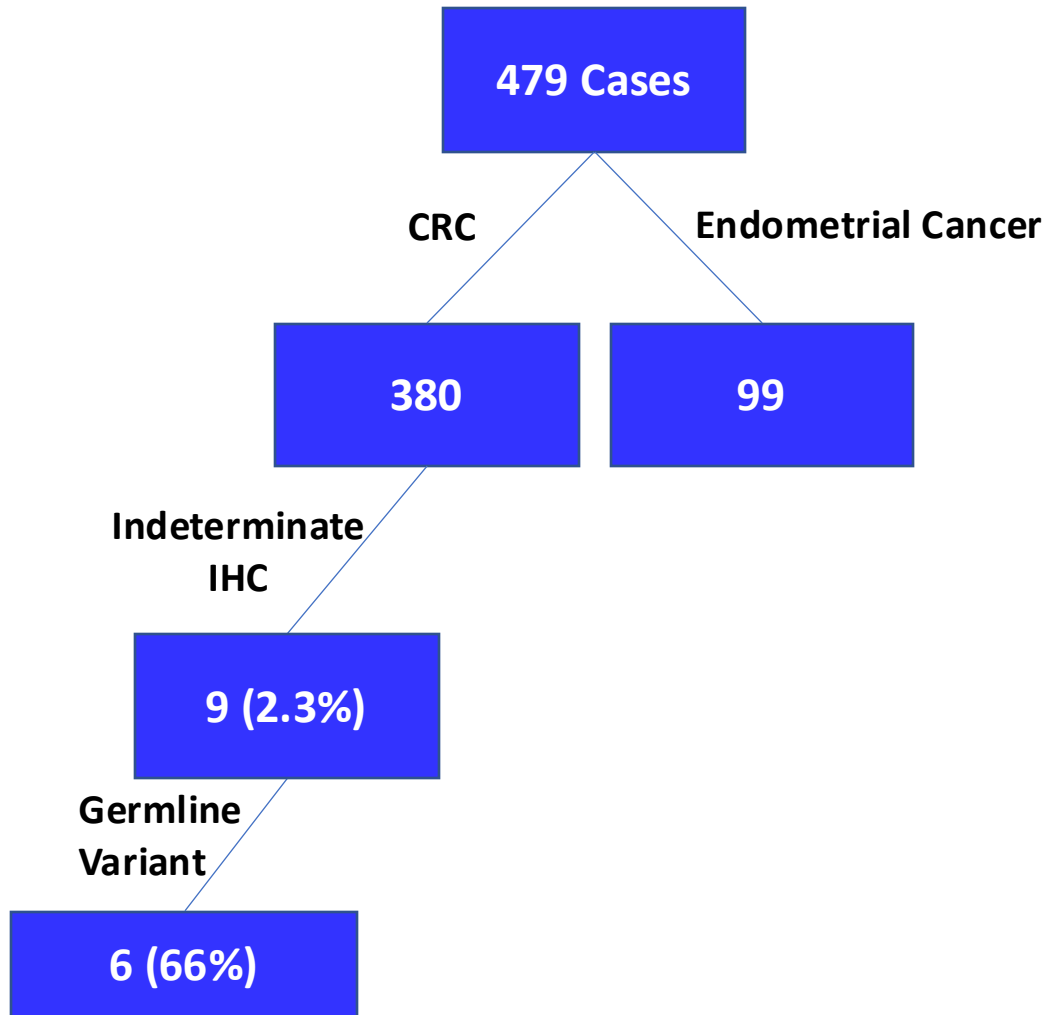
## **Preanalytical (technical)**

- Mislabeled, mix up
- Poor tissue handling/fixation
- Improper staining techniques

## **Interpretation**

- Lack of standardized interpretation guidelines
- Lack of experience
- Subjectivity or bias
- Lack of clinical information

# MMR and MSI Discordance: *Clue to an Underlying Germline Mutation*



## ***Weak or Indeterminate MMR IHC expression***

- Reported in ~2% of CRC in two large studies
- Appears to be an indicator of MSI-H
- Strong correlation with underlying germline mutation

Represents a potential pitfall and diagnostic challenge

## **Consensus to call MMR IHC “indeterminate”:**

- <10% positive or patchy staining
- Definitive staining in control tissues (stroma, etc)
- Reflex to MSI testing to confirm results

ARTICLE OPEN



# An unusual phenotype occurs in 15% of mismatch repair-deficient tumors and is associated with non-colorectal cancers and genetic syndromes

Marion Jaffrelot<sup>1,6</sup>, Nadim Farès<sup>1,2,3,6</sup>, Anne Cécile Brunac<sup>4</sup>, Anne Pascale Laurenty<sup>1</sup>, Marie Danjoux<sup>4</sup>, David Grand<sup>4</sup>, Samira Icher<sup>4</sup>, Julie Meilleroux<sup>4</sup>, Eliane Mery<sup>4</sup>, Etienne Buscail<sup>5</sup>, Charlotte Maulat<sup>5</sup>, Christine Toulas<sup>5</sup>, Pierre Vande Perre<sup>5</sup>, Edith Chipoulet<sup>5</sup>, Delphine Bonnet<sup>5</sup>, Anne Staub<sup>5</sup>, Rosine Guimbaud<sup>1,2,3,6</sup> and Janick Selves<sup>2,3,6</sup>✉

*Our study shows that “unusual dMMR tumors” are significantly more often associated with a genetic syndrome than classical dMMR tumors. We identified twice as many genetic syndromes (44.9%) in the unusual dMMR population as in the classical dMMR population (21.4%).*

# Summary

## **For unexpected and discordant lab results: *investigate further***

- Review the pathology reports, clinical history, consider sample mix-ups, wrong blocks, tumor sampling
- Inexperience, unclear interpretation guidelines, revisit bias/subjectivity

## **After you rule out an obvious error or root cause:**

- Consider other pathologies, consult the literature
- **“Atypical MMR staining” may indicate underlying biology**
- For ‘atypical’ ‘uncertain’ ‘indeterminate’ ‘discordant’ MMR IHC results reflex to MSI testing

**Critical to resolve because the patient’s response to therapy may not be optimized**

**UAB** THE UNIVERSITY OF  
ALABAMA AT BIRMINGHAM.

DEPARTMENT OF PATHOLOGY

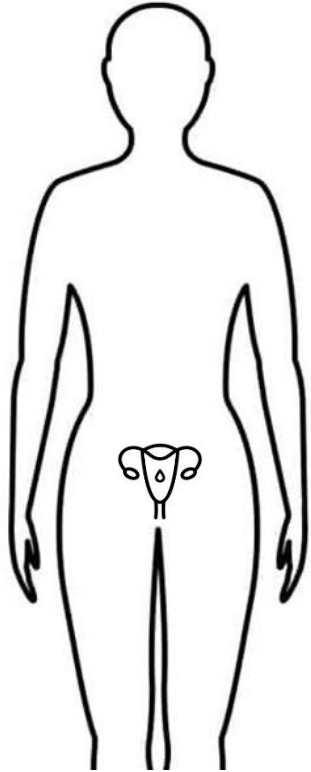
# Case 3

Discordant results and  
variable disease phenotype

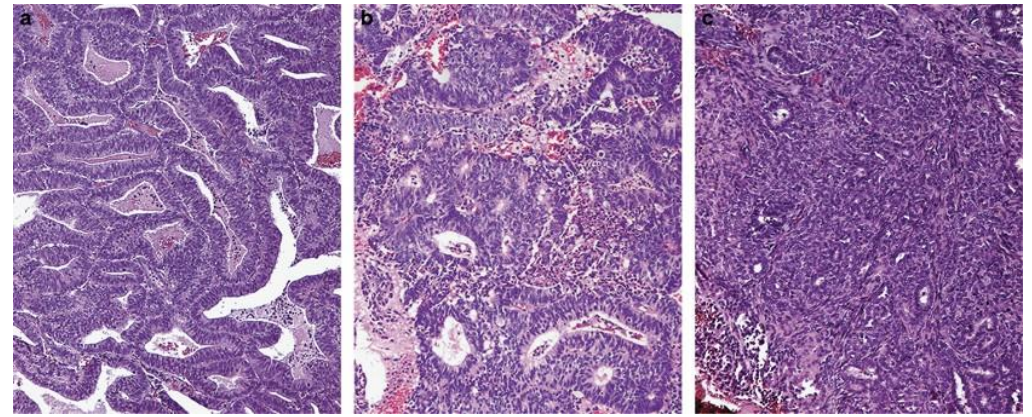


**Darshan Chandrashekar, PhD**  
Assistant Professor  
UAB Pathology

## Case: 2017 Endometrial Cancer



Endometrioid adenocarcinoma FIGO III  
0.7 cm greatest dimension  
3mm deepest invasion  
pT1a, pN0, pM (not assessed)



FIGO grade I

grade II

grade III

Malpica, A. How to approach the many faces of endometrioid carcinoma. *Mod Pathol* 29 (2016).

### TESTING: Discordant Results

#### MMR IHC

Loss of *MLH1* and *PMS2*  
*MLH1* hypermethylation

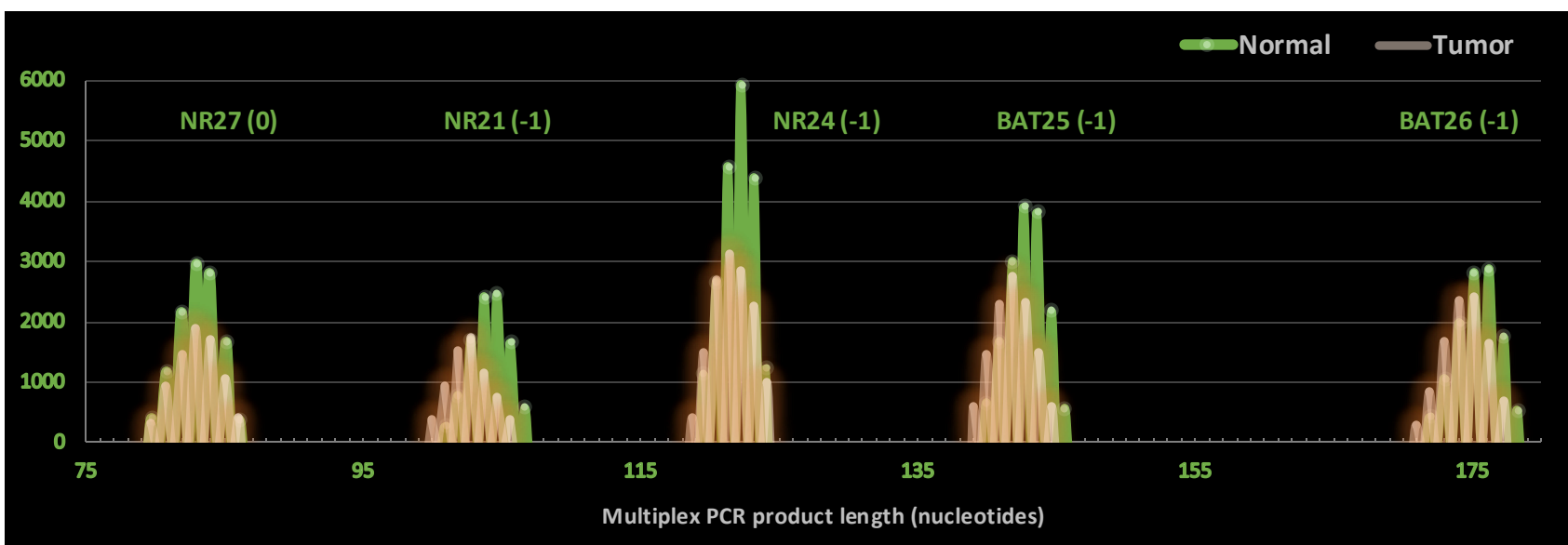
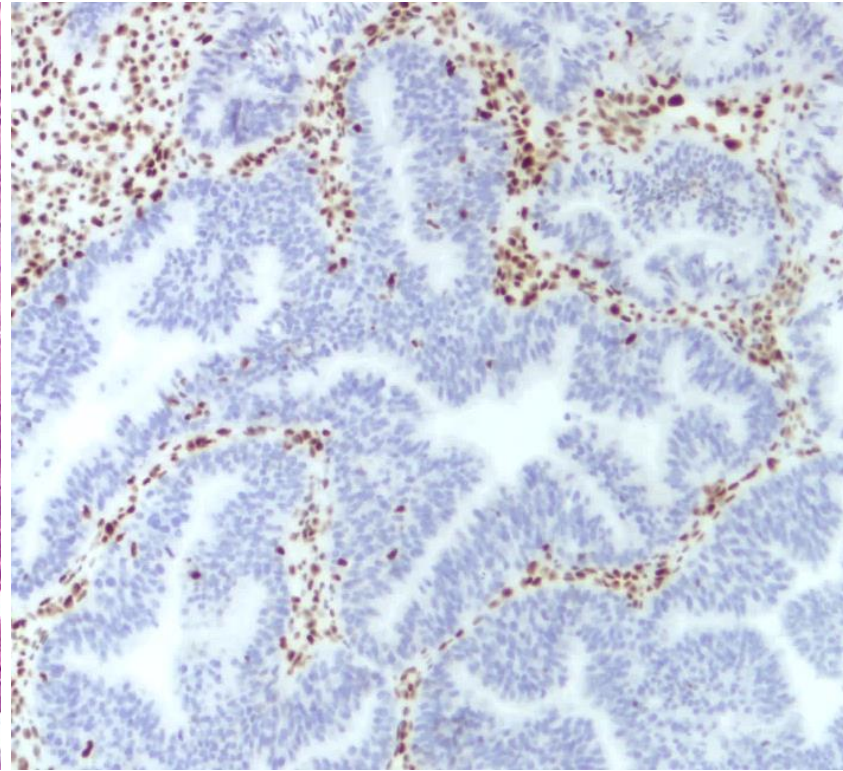
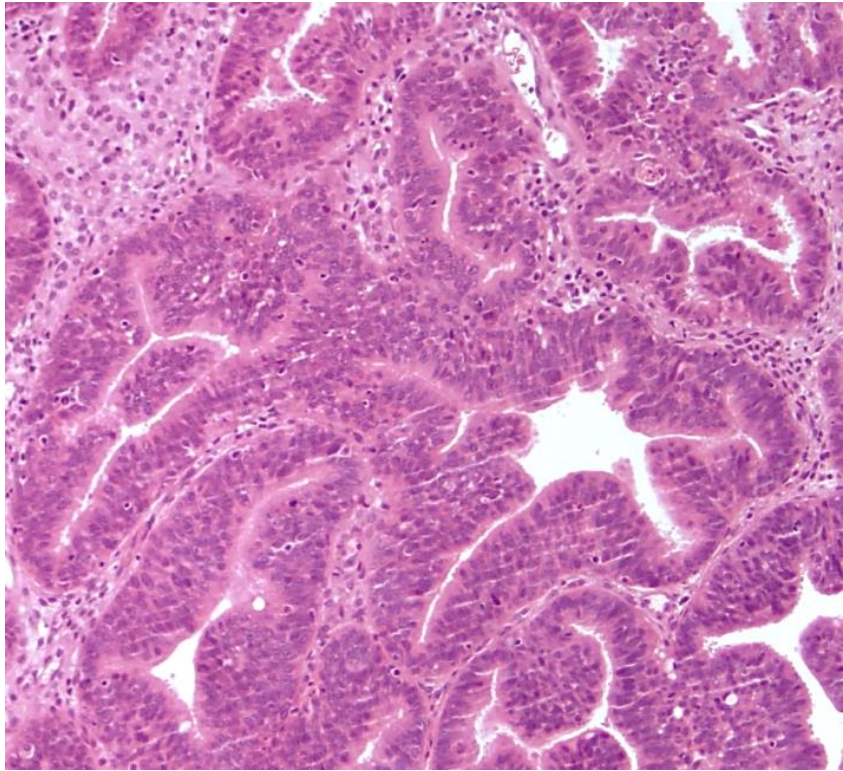


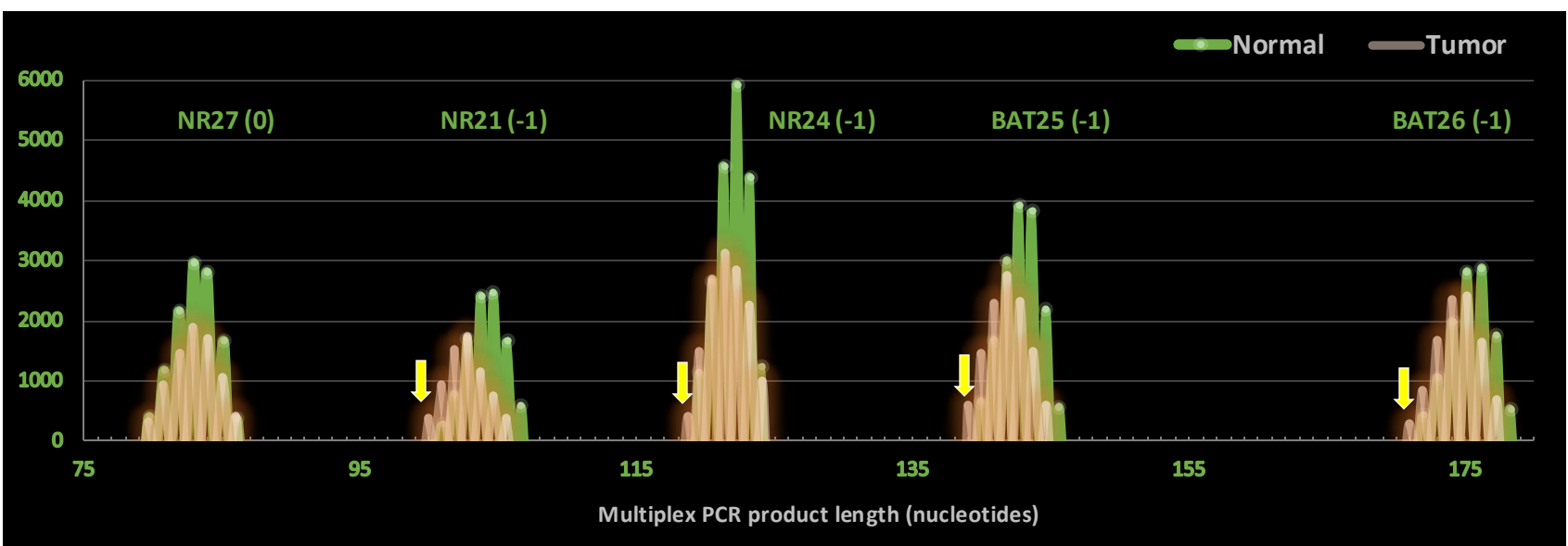
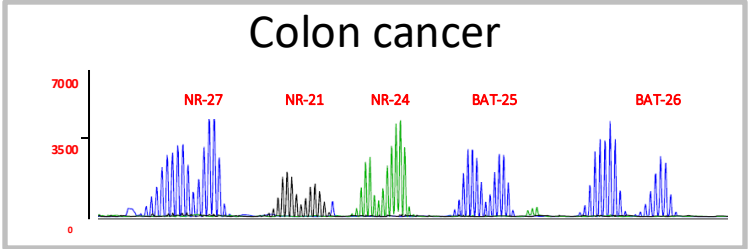
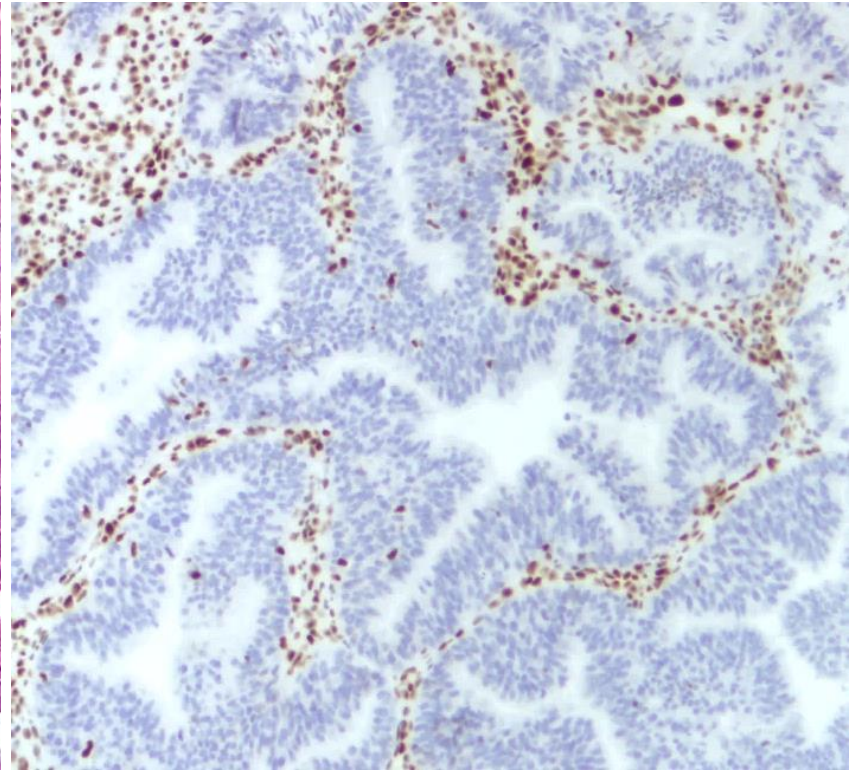
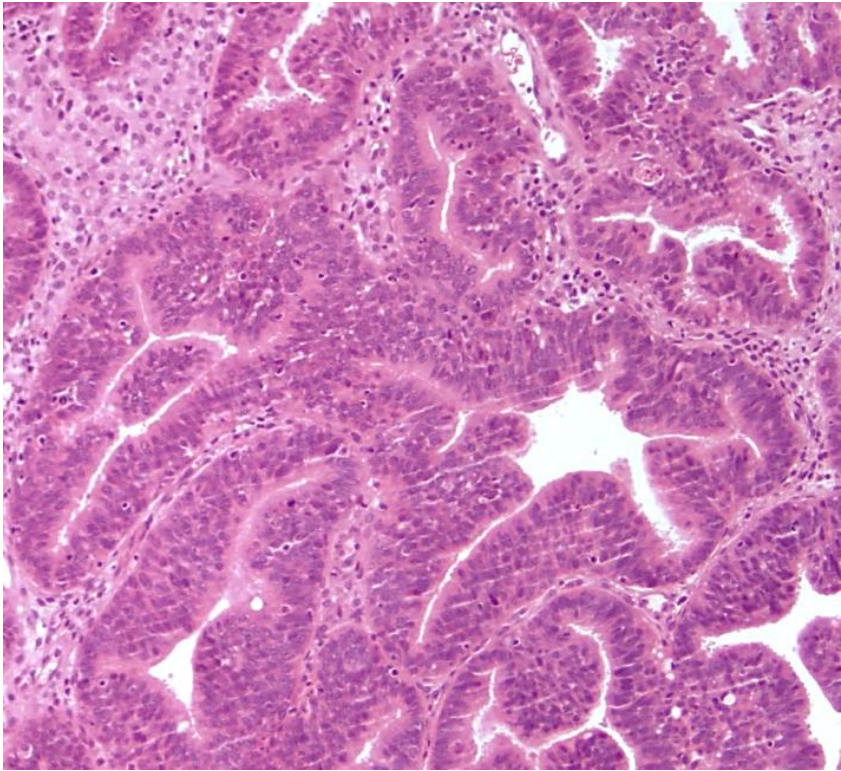
#### MSI status NGS

Microsatellite Stability (MSS)

## Discordant MMR (IHC) and MSI (NGS) are not well characterized in Endometrial Cancer

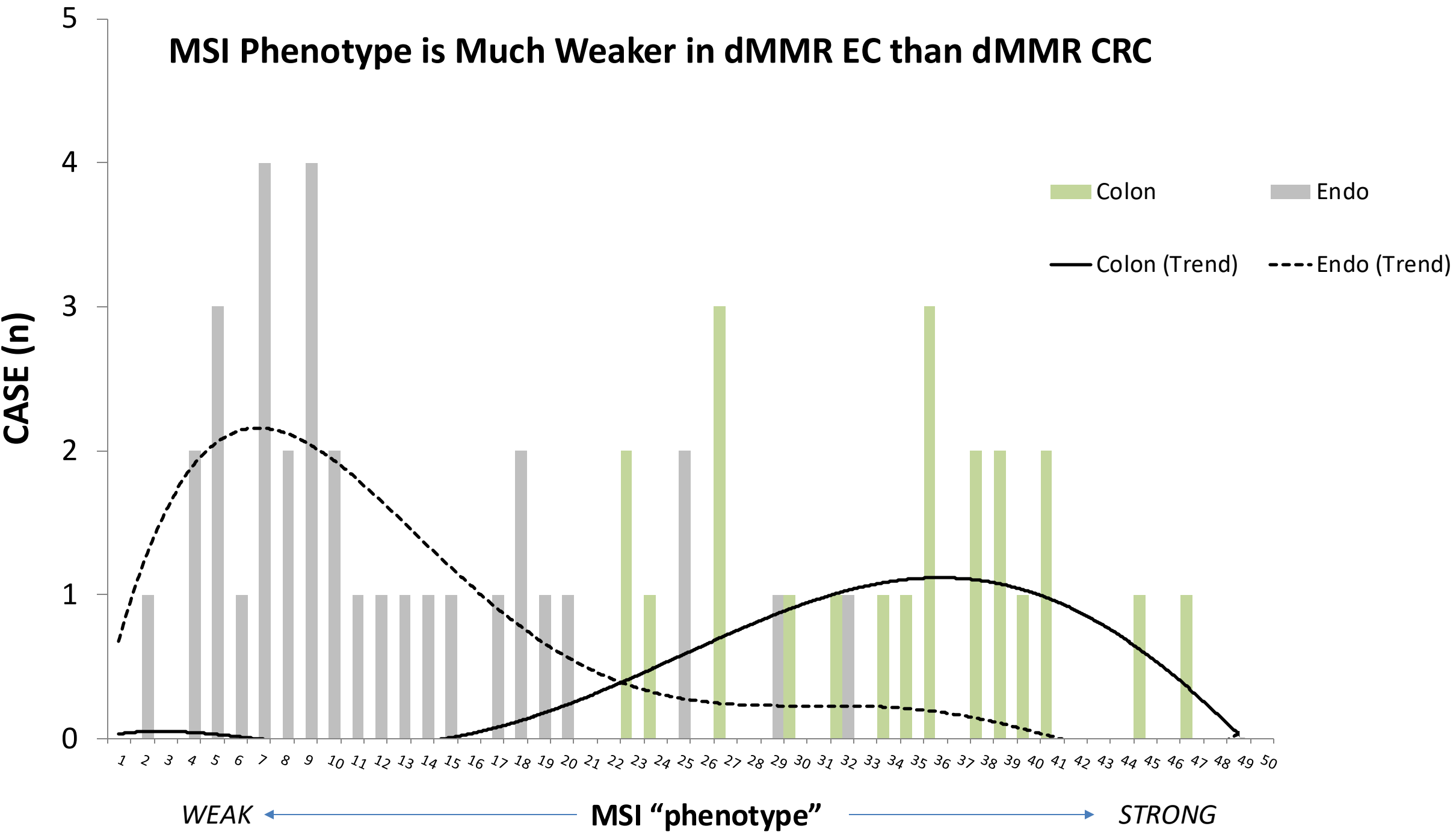
- Represents a potential false negative and risk to patient care
- NGS testing is often replacing MMR IHC or MSI PCR testing so important to understand





MSI Phenotype can be extremely weak in Endometrial Cancer

# MSI Phenotype is Much Weaker in dMMR EC than dMMR CRC



# T Cells in Endometrial Cancer

Cohort:

***“Weak”***  
*MSI Phenotype*

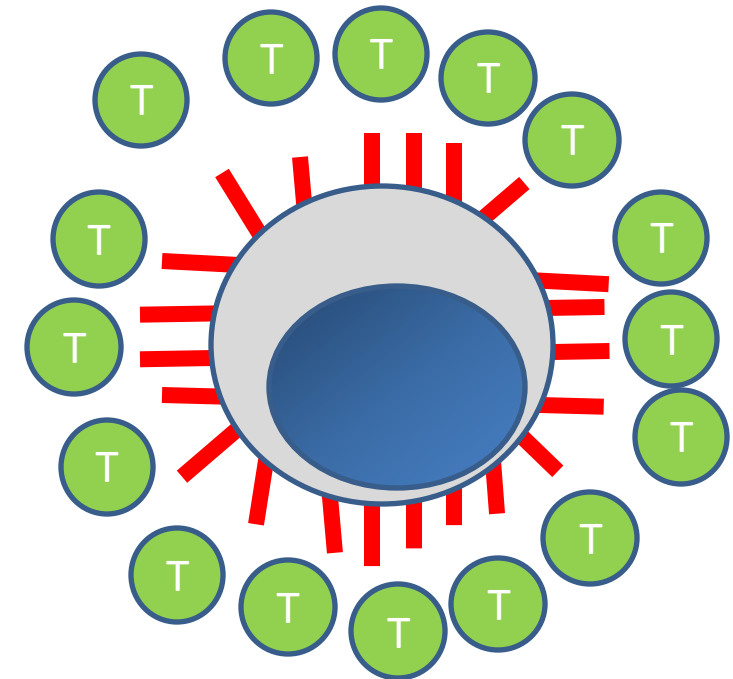
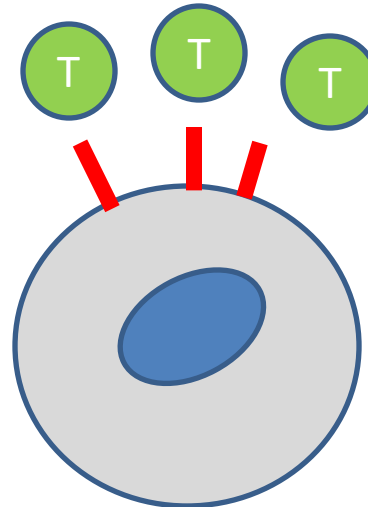
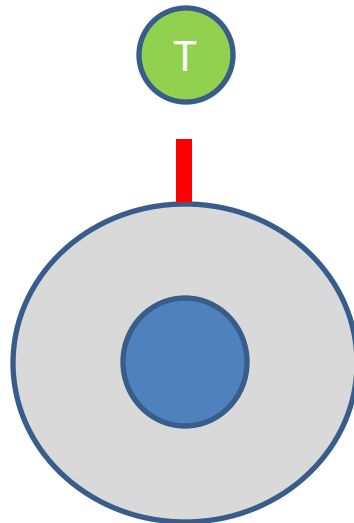
***“Strong”***  
*MSI Phenotype*

Immunogenicity:

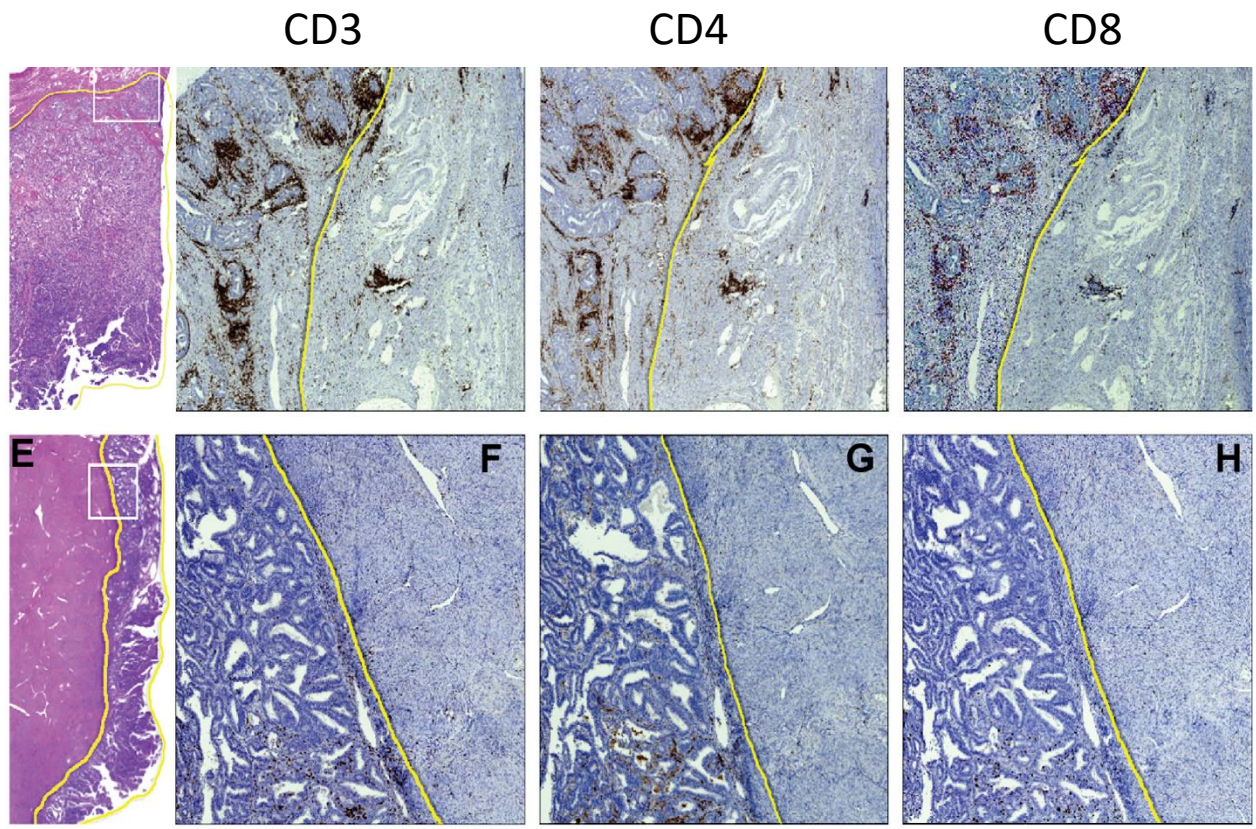
***Low***

***High***

Tumor Antigen



T: Tumor infiltrating lymphocytes



STRONG  
MSI

WEAK  
MSI

Human Pathology (2023) 139, 80–90



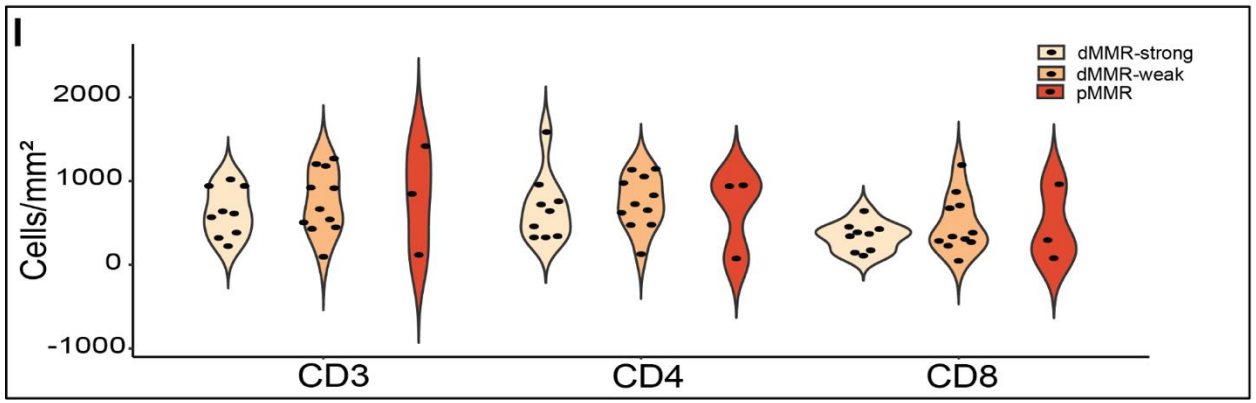
Original contribution

**Pathologic, immunologic, and clinical analysis of the microsatellite instability phenotype in endometrial carcinoma**☆

Alexander Craig Mackinnon Jr MD, PhD<sup>a,\*</sup>, Colin M. Johnson MD<sup>b</sup>, Adam Robin MD<sup>c</sup>, Lyle Christiansen MD<sup>c</sup>, Mehenaz Hanbazazh MD<sup>a,d</sup>, Rebekah M. Summey MD<sup>b</sup>, Darshan Chandrashaker PhD<sup>a</sup>, Shuko Harada MD<sup>a</sup>, Williams H. Bradley MD<sup>b,\*\*</sup>

<sup>a</sup> Department of Pathology, University of Alabama at Birmingham, Birmingham, AL, 35249, USA  
<sup>b</sup> Department of Obstetrics and Gynecology, Medical College of Wisconsin, Milwaukee, WI, 53226, USA  
<sup>c</sup> Department of Pathology, Medical College of Wisconsin, Milwaukee, WI, 53226, USA  
<sup>d</sup> Department of Pathology, Faculty of Medicine, University of Jeddah, Jeddah, Saudi Arabia

Received 9 March 2023; revised 16 May 2023; accepted 22 May 2023

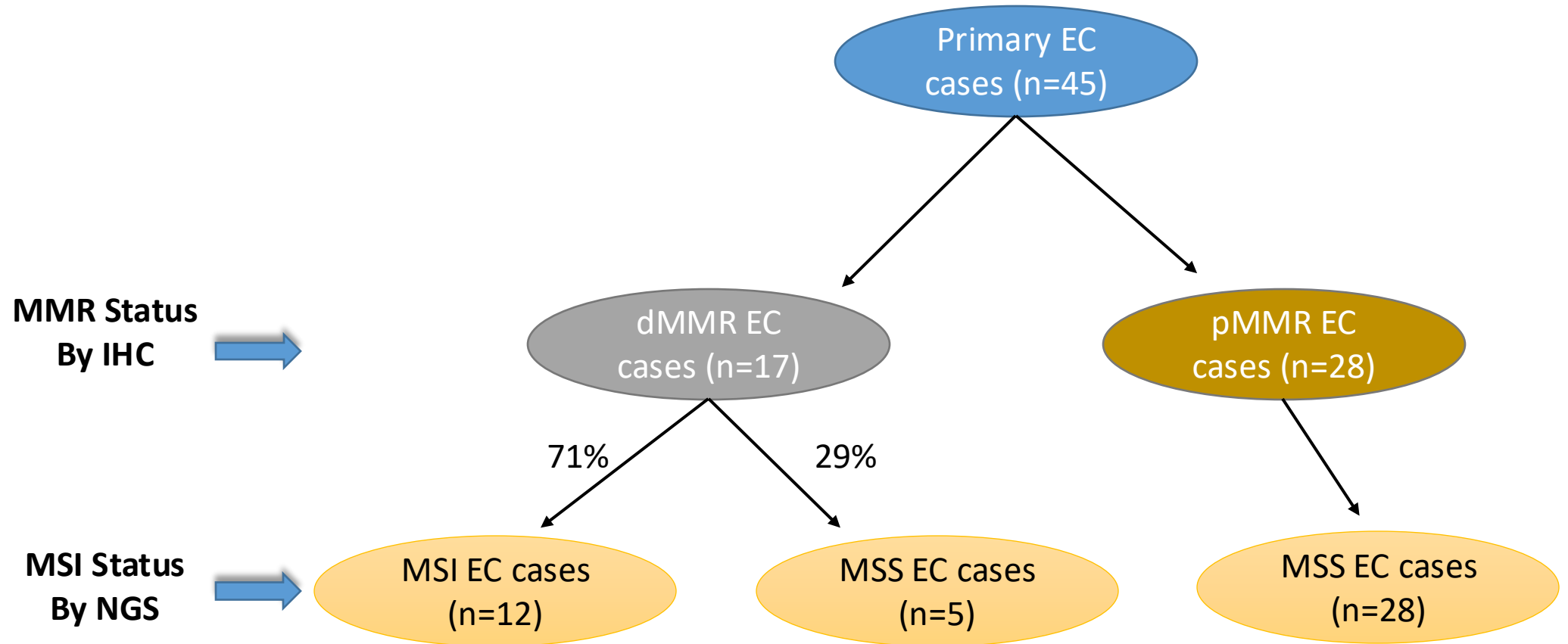


Number of Tumor  
Infiltrating T-cells Does  
**Not** Correlate with MSI  
Phenotype

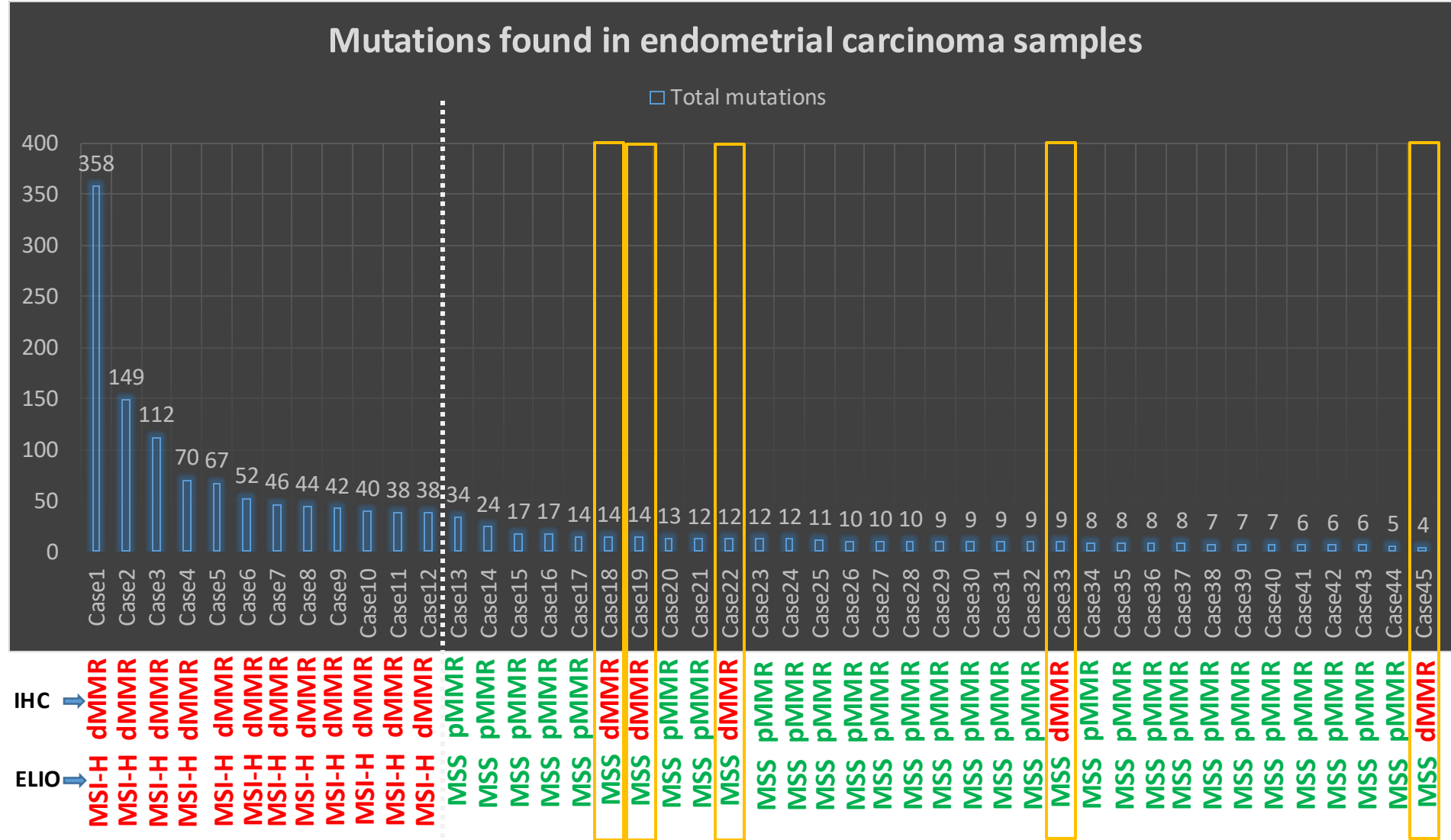
**Rationale:** MSI phenotype is weak in endometrial cancer and can be missed by molecular testing

**Aim**

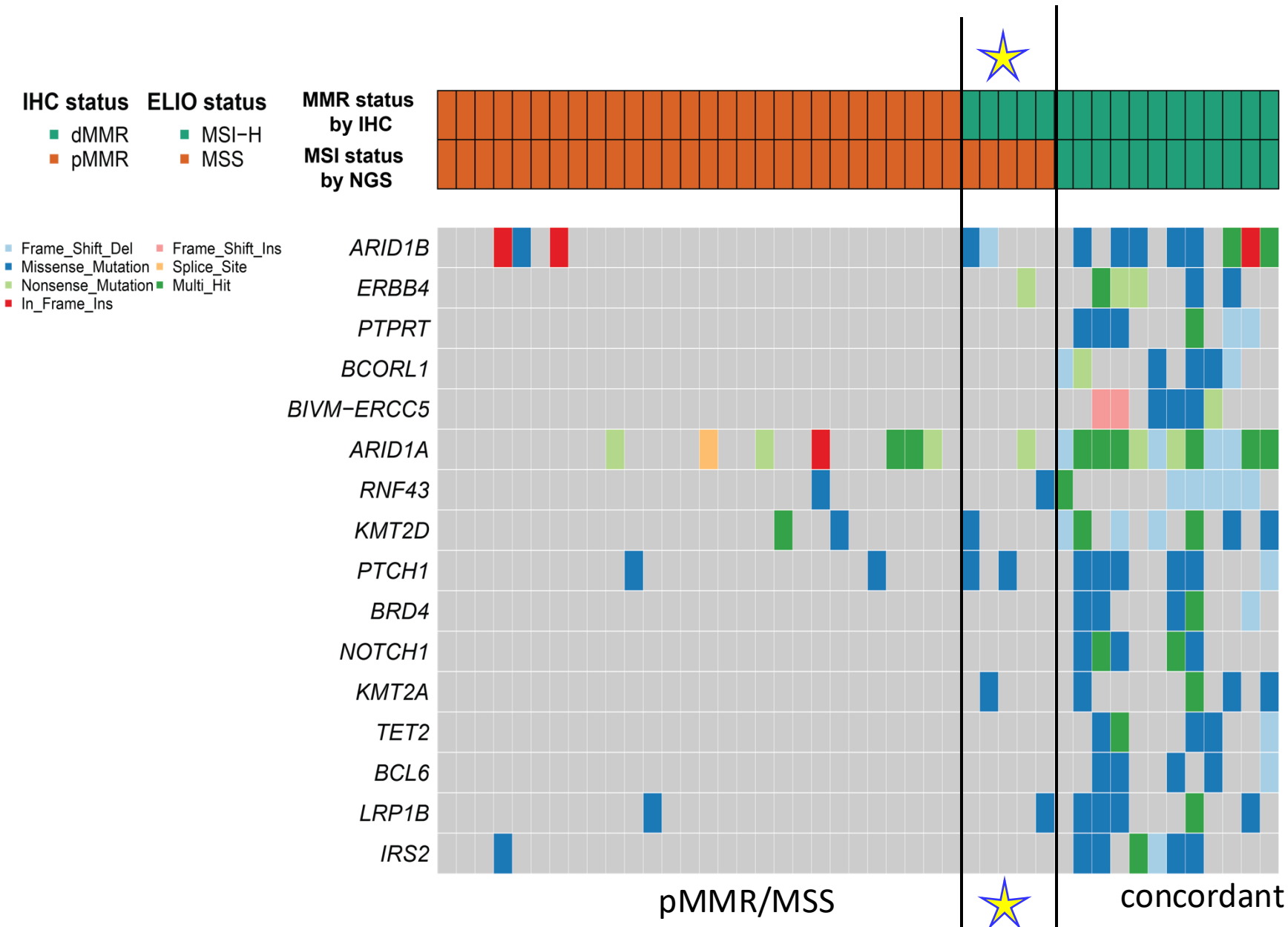
1. Determine the incidence of discordant MMR IHC and NGS-based detection of MSI status
2. Determine if endometrial cancer with weak MSI is a molecular subset of EC



# Mutational Load: dMMR/MSS cases show similar mutation burden as pMMR/MSS



# Discordant MMR/MSI have similar mutation spectrum as MSS cases



**pMMR (n=28)**   **dMMR (n=17)**   **P-value**

3 of 28	10 of 17	1.45E-03
0 of 28	6 of 17	1.52E-03
0 of 28	6 of 17	1.52E-03
0 of 28	6 of 17	1.52E-03
0 of 28	6 of 17	1.52E-03
7 of 28	13 of 17	1.58E-03
1 of 28	7 of 17	2.64E-03
2 of 28	8 of 17	3.10E-03
2 of 28	8 of 17	3.10E-03
0 of 28	5 of 17	5.06E-03
0 of 28	5 of 17	5.06E-03
0 of 28	5 of 17	5.06E-03
0 of 28	5 of 17	5.06E-03
1 of 28	6 of 17	8.06E-03

**2017: Endometrial Cancer**  
FIGO III, 0.7cm, pT1aN0

TMB: 3.1 Muts/MB

**Microsatellite STABLE**

*ARID1B* p.E1430GFs\*18

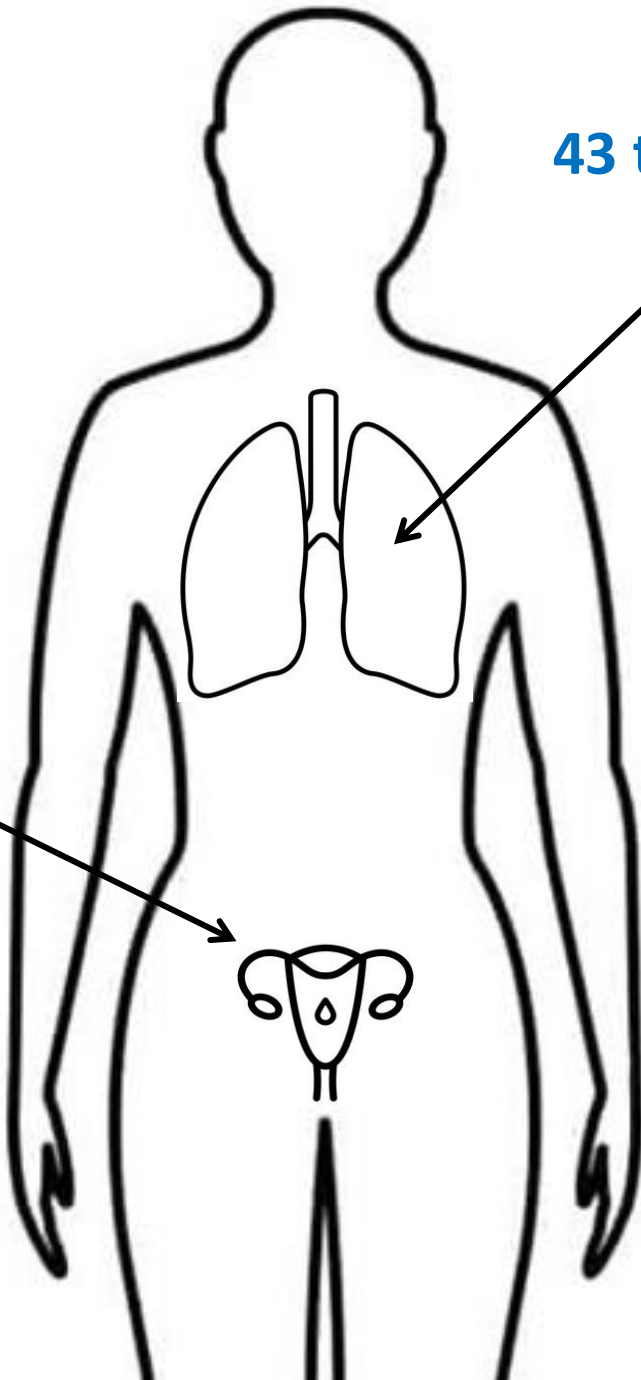
*ATM* p.Q754K

*KMT2A* p.N3794S

*PTEN* p.R130\*

**4 total**

**Patient 1**  
**Discordant dMMR/MSS**



**43 total**

**2021: Lung Metastasis**  
1.5cm

TMB: 41.5 Muts/MB

**Microsatellite INSTABILITY**

*ARID1B* p.E1430GFs\*18

*ATM* p.Q754K

*KMT2A* p.N3794S

*PTEN* p.R130\*

AKT1	GRIN2A	RAF1
BRCA2	H3F3A	RARA
CCND3	IGF2R	RECQL4
CHD4	JAK1	RNF43
CTCF	KDM6A	SLX4
DNMT1	KDM6A	SOX10
DOT1L	KMT2D	SPTA1
EPHA5	KMT2D	SUZ12
EZH2	NOTCH3	TET2
FANCM	NOTCH4	TET2
FAT1	PHOX2B	TSC2
GLI1	PREX2	WHSC1
GLI1	PTPRT	WHSC1

**2015: Endometrial Cancer**  
**FIGO II, 3cm, pT1aN0**

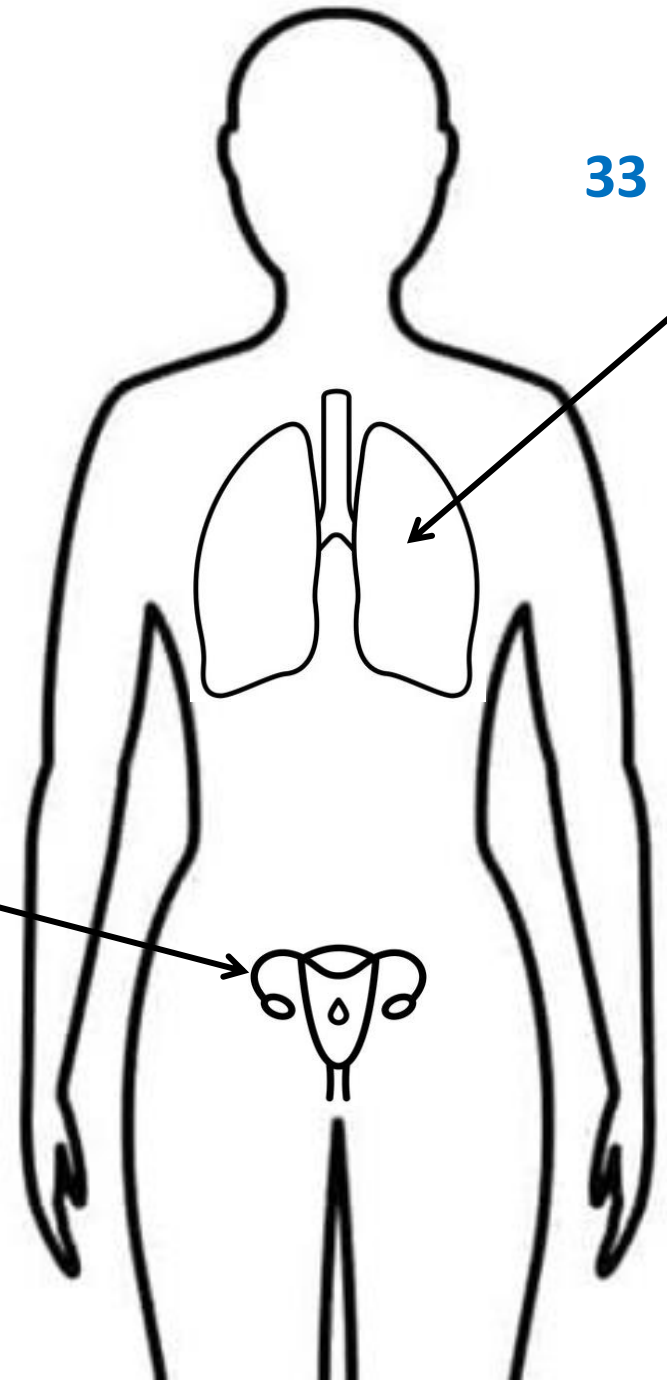
TMB: 13.1 Muts/MB

**Microsatellite STABLE**

- CTCF* p.N587fs (c.1760delA)
- MAX* p.R60Q (c.179G>A)
- KMT2D* p.I1279V (c.3835A>G)
- BCL2L1* p.A167T (c.499G>A)
- CTNNB1* p.T41I (c.122C>T)
- STK40* p.V140I (c.418G>A)
- TSHR* p.C549Y (c.1646G>A)
- PTCH1* p.W1312C (c.3936G>T)

**8 total**

**Patient 2**  
**Discordant dMMR/MSS**



**33 total**

**2021: Lung Metastasis**  
**4.5cm**

TMB: 36.2 Muts/MB

**Microsatellite INSTABILITY**

- CTCF* p.N587fs (c.1760delA)
- MAX* p.R60Q (c.179G>A)
- KMT2D* p.I1279V (c.3835A>G)
- BCL2L1* p.A167T (c.499G>A)
- MLH1* p.G463\* (c.1387G>T)
- MSH3* p.K383fs (c.1148delA)
- ABL1*     *ERG*     *PIK3C2B*
- ABL1*     *FGFR4*    *PIK3R1*
- ARID1B*   *FUBP1*    *PRKDC*
- MLH1*     *GATA2*    *PTEN*
- MSH3*     *GNA11*    *PTPRS*
- BCORL1*   *IL7R*     *RNF43*
- CIC*        *KDR*       *TOP2A*
- CSF3R*     *NCOR1*    *TSC2*
- CTCF*      *NT5C2*    *XIAP*
- EPHA5*     *PBRM1*

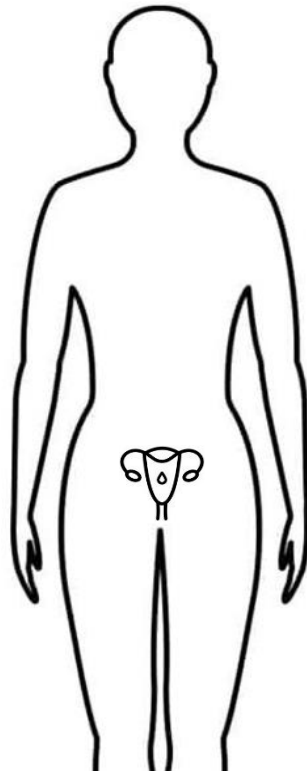
**Patient 3**  
**Concordant dMMR/MSI**

**2022: Endometrial Cancer**  
**FIGO II, 2.3cm, pT1aNX**

TMB: 45.4 Muts/Mb

**Microsatellite INSTABILITY**

34 Mutations

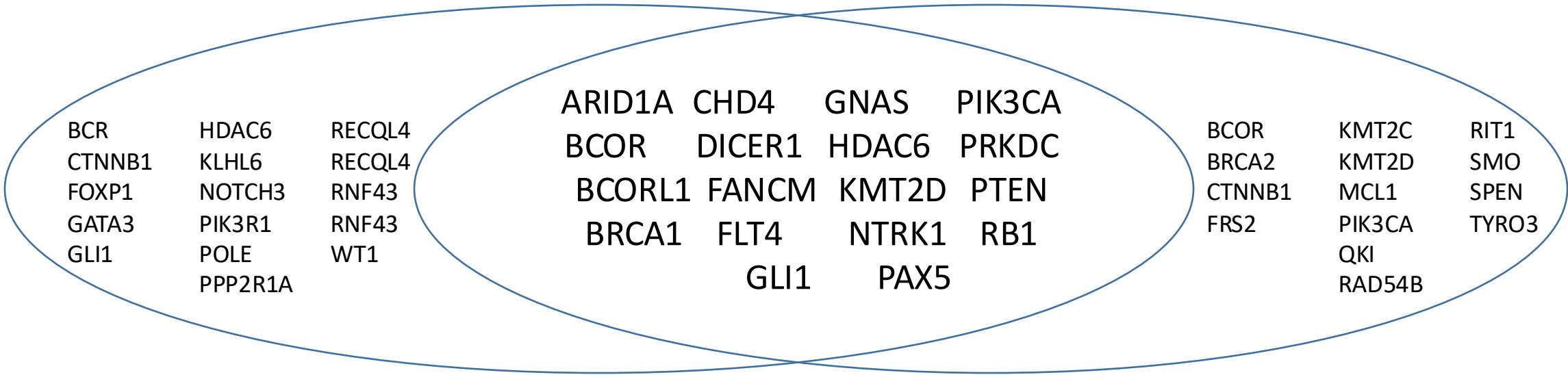


**2024: GI Metastasis**

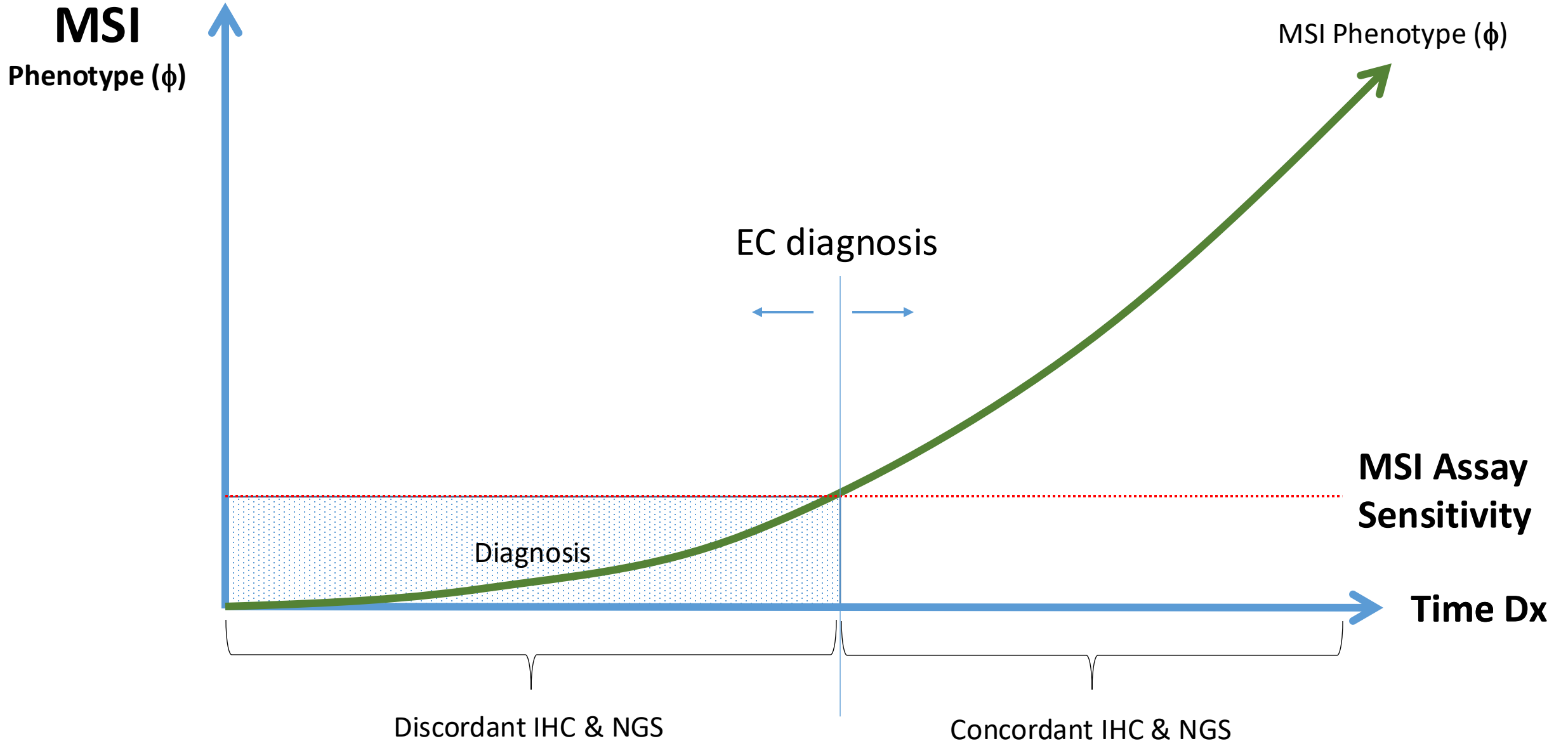
TMB: 31.5 Muts/MB

**Microsatellite INSTABILITY**

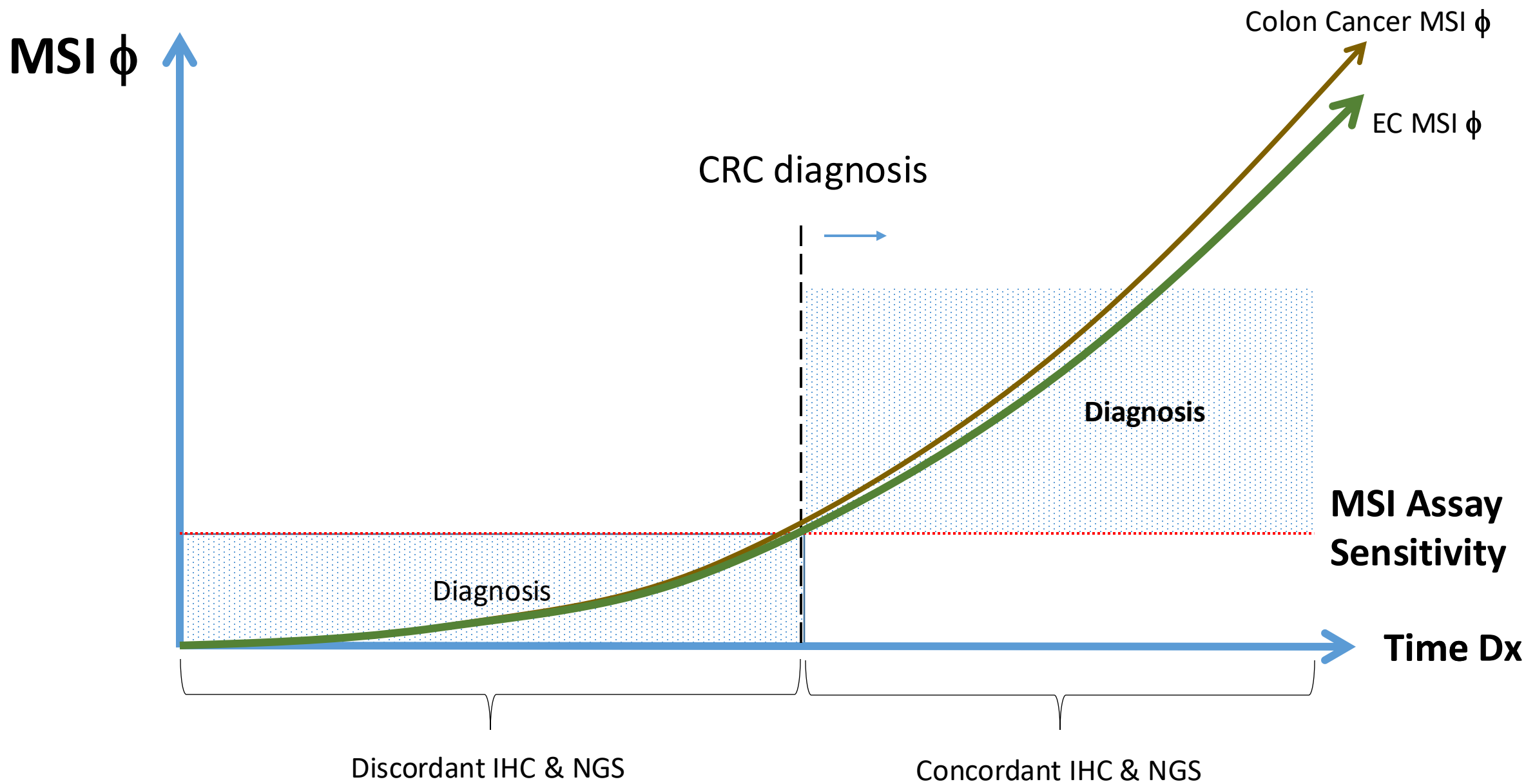
32 mutations



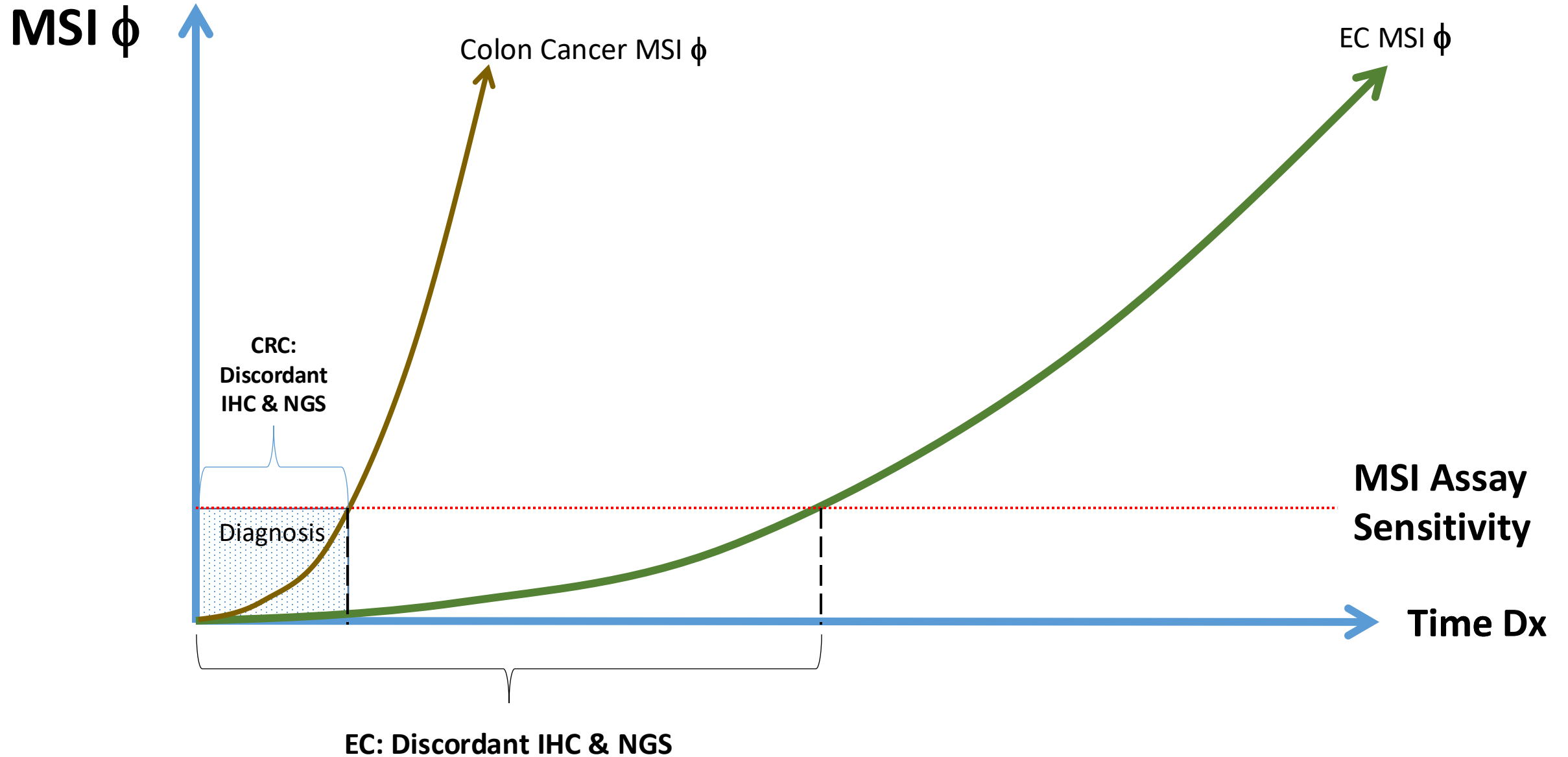
**MODEL 1:** EC comes to clinical attention before MSI accumulates  
EC diagnosed early will have dMMR/MSI discordance



**MODEL 1:** EC comes to clinical attention before MSI accumulates  
EC diagnosed early will have dMMR/MSI discordance  
*Maybe Colon Cancer is diagnosed when MSI phenotype is stronger*



**MODEL 2:** Rate of MSI accumulation (phenotypic expressivity) is variable across different cancers- e.g., CRC progresses faster



# Summary

**Tumor Heterogeneity:** Critical to rule out technical errors. Explore root causes and confirm result with orthogonal testing. Accurate results are essential for optimal therapy.

**Unusual or expected test results:** May represent clinically significant implications. Rule out technical errors. Evaluate interpretation guidelines. Consider and explore unusual biological explanations.

**Discordant Histology/IHC and Molecular Results:** NGS-based MSI and MMR IHC data identify a small subset of EC patients with weak MSI phenotypes. *This represents a potential pitfall: NGS MSI testing alone will miss dMMR cases (at UAB ~30% of dMMR missed by NGS).* Discordant cases have potential to progress over time suggesting dMMR/MSI is not the same good prognostic biomarker as in colon cancer.

**Thank you very much !**